

The “European Mandibular Angle” research project: the analysis of complications after unilateral angle fractures

Matteo Brucoli, MD, DDS,^a Paolo Boffano, MD,^a Andrea Pezzana, MD,^a Arnaldo Benech, MD, DDS, PhD,^a Pierre Corre, MD,^b Helios Bertin, MD,^b Petia Pechalova, MD, DDS, PhD,^c Nikolai Pavlov, MD, DDS,^d Petko Petrov, MD, DDS,^e Tiia Tamme, MD, DDS, PhD,^f Andrey Kopchak, MD, DDS, PhD,^g Anna Romanova^g, Eugen Shuminsky^g, Emil Dediol, MD, DDS,^h Marko Tarle, MD,^h Vitomir S. Konstantinovic, MD, DDS, PhD,ⁱ Drago Jelovac, DDS, MSC, PhD,ⁱ K. Hakki Karagozoglu, MD, DDS,^j and Tymour Forouzanfar, MD, DDS, PhD^j

Objective. The aim of this study was to analyze the complications and outcomes of surgical treatment of angle fractures managed at departments of maxillofacial surgery in several European countries.

Study Design. Patients hospitalized with unilateral isolated angle fractures between 2013 and 2017 were included. The following data were recorded: gender and age of patients, fracture etiology, presence of the third molar, maxillomandibular fixation, osteosynthesis technique, and complications.

Results. In total, 489 patients were included in the study. The Champy technique was found to be the most frequently chosen osteosynthesis technique. Sixty complications were observed, at a rate of 12.3%. Complications were associated with the absence of third molars ($P < .05$). Instead, the Champy technique was associated with fewer complications ($P < .05$), in comparison with the other adopted techniques.

Conclusions. The management of angle fractures still represents a challenging task with a significant complication rate. The Champy technique still seems to be a valid option for the treatment of such injuries. (Oral Surg Oral Med Oral Pathol Oral Radiol 2019;000:1–4)

A variety of treatment philosophies have been described for the management of mandibular angle fractures.^{1,2} To date, the so-called Champy technique has probably been the most commonly used method of fixation.¹⁻⁴

However, despite the progress in the treatment methods and fixation systems for maxillofacial trauma, the

optimal method for the treatment of mandibular angle fractures is still being debated.¹⁻⁹

Furthermore, treatment for mandibular angle fracture is challenging because it seems to be associated with the highest rate of complications, such as infection, malunion, malocclusion, and facial nerve damage reported to range from 0% to 32%.¹⁻⁹

Most analyses of complications after open reduction and internal fixation of angle fractures reported the occurrence of additional mandibular fractures, which may be an important confounding variable and thus may affect the treatment outcome. In fact, an additional fracture may contribute to instability at the fracture site, leading to impaired bone healing that predisposes the patient to infection or malocclusion.¹⁻⁸ Only a study of isolated angle fractures would allow us to establish the true complication rate for these fractures.¹⁻⁶

Therefore, several European centers that had already demonstrated research experience in maxillofacial trauma decided to collaborate on a multicenter research project about mandibular angle fractures in Europe.¹⁰⁻²⁸

^aDivision of Maxillofacial Surgery at the University of Eastern Piedmont, Novara, Italy.

^bService de Stomatologie et Chirurgie Maxillo-faciale at the Chu de Nantes, Nantes, France.

^cDepartment of Oral Surgery, Faculty of Dental Medicine, Medical University, Plovdiv, Bulgaria.

^dPrivate Practice of Oral Surgery, Plovdiv, Bulgaria.

^eDepartment of Maxillofacial Surgery, Faculty of Dental Medicine, Medical University, Plovdiv, Bulgaria.

^fDepartment of Maxillofacial Surgery, Stomatology Clinic, Tartu University, Tartu, Estonia.

^gDepartment for Oral and Maxillofacial Surgery at the Bogomolets National Medical University, Kiev, Ukraine.

^hDepartment of Maxillofacial Surgery at the University Hospital Dubrava, Zagreb, Croatia.

ⁱThe Clinic of Maxillofacial Surgery of the School of Dentistry at the University of Belgrade, Belgrade, Serbia.

^jDepartment of Oral and Maxillofacial Surgery/Pathology, VU University Medical Center and Academic Centre for Dentistry Amsterdam (ACTA), Amsterdam, The Netherlands.

Received for publication Dec 19, 2018; accepted for publication Feb 25, 2019.

© 2019 Elsevier Inc. All rights reserved.

2212-4403/\$-see front matter

<https://doi.org/10.1016/j.oooo.2019.02.027>

Statement of Clinical Relevance

The management of angle fractures still represents a challenging task for surgeons with a remarkable complication rate.

The aim of this multicenter study was to analyze the complications and outcomes of surgical treatment of angle fractures managed at departments of oral and maxillofacial surgery in several European countries to lower confounding variables and to obtain a larger sample size. The results of this multicenter collaboration to study maxillofacial trauma management over a 5-year period are presented here.

MATERIAL AND METHODS

The present study was conducted at departments of oral and maxillofacial surgery in several European countries: the Division of Maxillofacial Surgery at the University of Eastern Piedmont (Novara, Italy); the Department of Oral and Maxillofacial Surgery/Pathology at the VU University Medical Center and Academic Centre for Dentistry Amsterdam (Amsterdam, The Netherlands); the Department of Maxillofacial Surgery at the University Hospital Dubrava (Zagreb, Croatia); the Clinic of Maxillofacial Surgery of the School of Dentistry at the University of Belgrade (Belgrade, Serbia); the Department of Maxillofacial Surgery at the Medical University (Plovdiv, Bulgaria); the Department for Oral and Maxillofacial Surgery at the Bogomolets National Medical University (Kiev, Ukraine); and the Service de Stomatologie et Chirurgie Maxillo-faciale at the Chu de Nantes (Nantes, France). This study was based on a systematic computer-assisted database, which consisted of information from the records of all patients hospitalized for mandibular angle fractures in the involved maxillofacial surgical units across Europe, between January 1, 2013, and December 31, 2017. Criteria for inclusion were as follows: unilateral isolated fracture of the mandibular angle, absence of further maxillofacial fractures, and treatment at a hospital.

The following data were recorded for each patient: sex, age, etiology, side of angle fracture, presence of third molar (impacted or not impacted) in the angle fracture line, type of performed maxillomandibular fixation (intermaxillary fixation screws, arch bars, other), type of osteosynthesis technique (Champy technique, 2 miniplates, superior lateral border, inferior border, reconstruction plate, Kirschner wire, other), and complications.

The following categories of cause of injury were considered: fall, motor vehicle accident, assault, sport injury, work injury, and other causes. Patient characteristics were analyzed by using descriptive statistics. Statistical analysis was used to search for associations among multiple variables. Statistical significance was determined by using the χ^2 or Fisher's exact test, if the sample sizes were too small. Statistical significance was set at $P = .05$. Institutional review board approval was exempted. We followed the Helsinki Declaration guidelines.

RESULTS

In total, 489 patients (448 males, 41 females) met the inclusion criteria during the study period (2013–2017) and were included in the study. Mean age was 30.7 years (median 28; standard deviation 12.5; range 15–91 years). In the study sample, 276 left angle fractures and 213 right angle fractures were observed.

Most patients (281 patients [57.5%]) did not report any recreational habits, whereas the remaining 208 reported smoking and alcohol and/or drug use, as shown in Figure 1.

As for etiology, the most frequent cause of injury was assault in 308 patients, followed by falls (83 patients), sport accidents (35 patients), motor vehicle accidents (25 patients), work accidents (6 patients), and other causes (32 patients) (Figure 2).

The third molar was present in the angle fracture line in 326 patients. In 143 patients it was impacted, and in 183, it was not impacted (Table I).

As for surgical technique, the Champy technique was the most frequently chosen (49%), followed by the 2-plate technique (32%) and by superior lateral border plating (13%) (Figure 3).

In total, 60 complications were observed during follow-up, at a rate of 12.3%. The list of encountered complications is depicted in Table II.

No significant association was found between recreational habits and complications, or between age and complications. Instead, complications were associated with absence of the third molars in the angle fracture line ($P < .05$).

Finally, there was a statistically significant association between the Champy osteosynthesis technique and fewer complications ($P < .05$), in comparison with the other adopted techniques.

DISCUSSION

The purpose of mandibular angle fracture fixation is to restore occlusion and temporomandibular joint functions with minimal disability and complications. Currently, there is no standardized protocol to manage this fracture.²⁻⁶

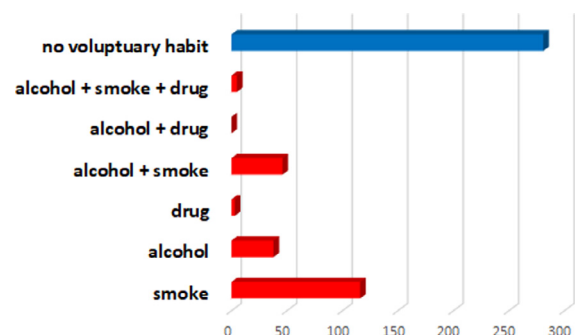


Fig. 1. Recreational habits in the study population.

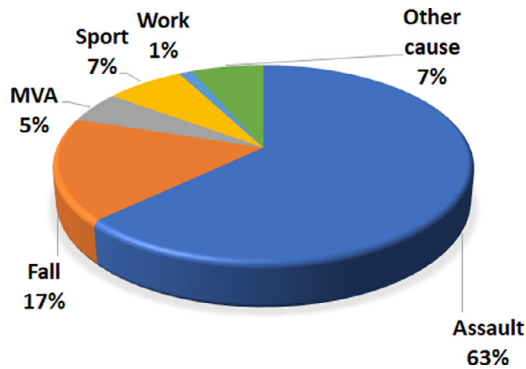


Fig. 2. Etiologic factors within the study population. MVA, motor vehicle accident.

Table I. Presence of third molars in angle fracture line and complications

Third molar present	N	Complications	No complications
No	163	29	134
Yes, erupted	183	17	166
Yes, impacted	143	14	129

It is widely acknowledged that several complications (up to 32%) can be associated with angle fractures, in the form of infection, malunion, malocclusion, or facial nerve damage.²⁻⁶

Previous studies included treatments of mandibular angle fractures associated with further mandibular fractures. However, when the mandible has multiple fractures, the treatment of angle fractures may be modified to fit the forces acting on the mandible during its function because of the increased instability in the fracture site.¹⁻⁹ Therefore, studies that select only isolated angle fractures, such as our study, can provide results that are more reliable. The multicenter nature of our research project allowed us to increase the study population and to lower the possible bias.

Surgical treatment of mandibular angle fractures can be technically challenging. Open reduction and internal fixation can be performed with a variety of approaches and plating techniques. The decisions regarding

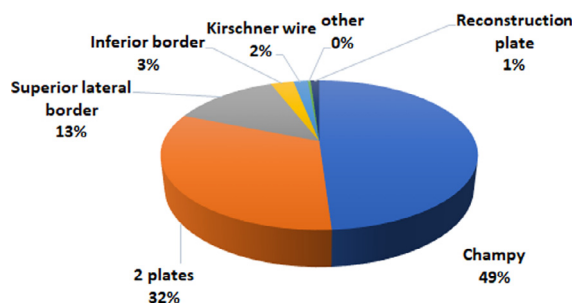


Fig. 3. Percentages of adopted plating techniques.

Table II. Encountered complications in the study population

Plate exposure	15
Infection	19
Malocclusion	10
Anesthesia-related	9
Osteomyelitis	3
Malunion	2
Wound dehiscence	2

approach and plating are often dictated by fracture orientation, number of fracture segments, type of fracture, and amount of displacement. In this study, we attempted to reduce the angle fracture variables as much as possible by including only noncomminuted and unilateral isolated angle fractures.¹⁻⁸

The overall rate of major complications from our study population was 12.3%, which is within the range of 0% to 32% documented in other studies.¹⁻⁸

Against any hypothesis, no significant association was found between recreational habits and complications. Instead, quite inexplicably, complications were associated with absence of the third molars in the angle fracture line ($P < .05$). It may be simpler to hypothesize that the presence of the third molar in the angle fracture lines represents a risk factor, at least for infections, malocclusion, or plate exposure. However, our data contradicted this theory, in agreement with other reports in the recent literature.⁵⁻⁹ In fact, the decrease in complication rates in cases with third molar involvement can be attributed to osteosynthesis and the use of antibiotics. Furthermore, although it could be speculated that the absence of the third molar could be associated with older age and that complications could therefore result from the older age of the patients, our statistical analysis disagreed with this hypothesis as well.

Finally, there was a statistically significant association between the Champy osteosynthesis technique and fewer complications ($P < .05$), in comparison with other techniques. Therefore, a miniplate placed according to the Champy technique seemed to significantly reduce the incidence of overall morbidity compared with other osteosynthesis techniques for the fixation of isolated fractures of the mandibular angle.

There are some limitations associated with the nature of our study, such as the high number of the variables considered. However, our attempt to have the most uniform study population still represents an adequate number and homogeneity of the study sample.

CONCLUSIONS

The management of angle fractures still represents a challenging task for surgeons, with a significant complication rate. The Champy technique still seems to be

a valid option, if not one of the best options, for the open reduction and internal fixation of the fractures of the mandibular angle. Further multicenter studies are needed to obtain more appropriate and definitive results.

REFERENCES

1. El-Anwar MW, Sweed AH. Simple percutaneous transbuccal approach for management of mandibular angular fracture. *J Craniofac Surg*. 2017;28:1035-1037.
2. Boffano P, Rocca F, Zavattero E, et al. European Maxillofacial Trauma (EURMAT) project: a multicentre and prospective study. *J Craniomaxillofac Surg*. 2015;43:62-70.
3. Al-Moraissi EA, El-Sharkawy TM, El-Ghareeb TI, Chrcanovic BR. Three-dimensional versus standard miniplate fixation in the management of mandibular angle fractures: a systematic review and meta-analysis. *Int J Oral Maxillofac Surg*. 2014;43:708-716.
4. Elsayed SA, Mohamed FI, Khalifa GA. Clinical outcomes of three different types of hardware for the treatment of mandibular angle fractures: a comparative retrospective study. *Int J Oral Maxillofac Surg*. 2015;44:1260-1267.
5. An W, Ainiwaer A, Wusiman P, Ali G, Moming A. Surgical management of mandibular angle fractures. *J Craniofac Surg*. 2018;29:1702-1708.
6. Ayali A, Erkmen E. Biomechanical evaluation of different plating methods used in mandibular angle fractures with 3-dimensional finite element analysis: favorable fractures. *J Oral Maxillofac Surg*. 2017;75:1464-1474.
7. Chen CL, Zenga J, Patel R, Branham G. Complications and reoperations in mandibular angle fractures. *JAMA Facial Plast Surg*. 2018;20:238-243.
8. Sawatari Y, Marwan H, Alotaibi F, Christensen J, Gannon J, Peleg M. The use of three-dimensional strut plates for the management of mandibular angle fractures: a retrospective analysis of 222 patients. *Int J Oral Maxillofac Surg*. 2016;45:1410-1417.
9. Zanakis S, Tasoulas J, Angelidis I, Dendrinis C. Tooth in the line of angle fractures: the impact in the healing process. A retrospective study of 112 patients. *J Craniomaxillofac Surg*. 2015;43:113-116.
10. Bakardjiev A, Pechalova P. Maxillofacial fractures in Southern Bulgaria—a retrospective study of 1706 cases. *J Craniomaxillofac Surg*. 2007;35:147-150.
11. Tabaković SZ, Konstantinović VS, Radosavljević R, Movrin D, Hadžistević M, Hatab N. Application of computer-aided designing and rapid prototyping technologies in reconstruction of blowout fractures of the orbital floor. *J Craniofac Surg*. 2015;26:1558-1563.
12. Kokemueller H, Konstantinovic VS, Barth EL, et al. Endoscope-assisted transoral reduction and internal fixation versus closed treatment of mandibular condylar process fractures—a prospective double-center study. *J Oral Maxillofac Surg*. 2012;70:384-395.
13. Konstantinović VS, Puzović D, Anićić B, Jelovac DB. Epidemiological, clinical, and forensic aspects of chainsaw, circular saw, and grinding saw injuries in the maxillofacial region. *J Craniofac Surg*. 2010;21:1029-1032.
14. Merlet FL, Grimaud F, Pace R, et al. Outcomes of functional treatment versus open reduction and internal fixation of condylar mandibular fracture with articular impact: a retrospective study of 83 adults. *J Stomatol Oral Maxillofac Surg*. 2018;119:8-15.
15. Boffano P, Corre P, Righi S. The role of intra-articular surgery in the management of mandibular condylar head fractures. *Atlas Oral Maxillofac Surg Clin North Am*. 2017;25:25-34.
16. Corre P, Arzul L, Khonsari RH, Mercier J. Facial trauma and multiple trauma. *Soins*. 2013(778):43-45.. [in French].
17. Malanchuk VO, Kopchak AV. Risk factors for development of infection in patients with mandibular fractures located in the tooth-bearing area. *J Craniomaxillofac Surg*. 2007;35:57-62.
18. Dediol E. The role of three-dimensional computed tomography in evaluating facial trauma. *Plast Reconstr Surg*. 2012;129:354.. e-355 e.
19. Bins A, Oomens MA, Boffano P, Forouzanfar T. Is there enough evidence to regularly apply bone screws for intermaxillary fixation in mandibular fractures? *J Oral Maxillofac Surg*. 2015;73:1963-1969.
20. Salentijn EG, Peerdeman SM, Boffano P, van den Bergh B, Forouzanfar T. A ten-year analysis of the traumatic maxillofacial and brain injury patient in Amsterdam: incidence and aetiology. *J Craniomaxillofac Surg*. 2014;42:705-710.
21. Salentijn EG, Collin JD, Boffano P, Forouzanfar T. A ten year analysis of the traumatic maxillofacial and brain injury patient in Amsterdam: complications and treatment. *J Craniomaxillofac Surg*. 2014;42:1717-1722.
22. Brucoli M, Boffano P, Bonaso M, Benech A. The management of a Y-shaped fracture of the mandibular ramus. *Otorinolaringologia*. In Press. <https://doi.org/10.23736/S0392-6621.18.02196-3>
23. Brucoli M, Boccafoschi F, Boffano P, Broccardo E, Benech A. The Anatomage Table and the placement of titanium mesh for the management of orbital floor fractures. *Oral Surg Oral Med Oral Pathol Oral Radiol*. 2018;126:317-321.
24. Brucoli M, Boffano P, Magnano M, Mistretta R, Benech R, Benech A. The management of a high-risk patient with edentulous mandibular fractures. *Otorinolaringologia*. 2019;69:42-44.
25. Brucoli M, Nestola DF, Baragiotta N, Boffano P, Benech A. Maxillofacial fractures: epidemiological analysis of a single centre experience. *Otorinolaringologia*. 2018;68:132-137.
26. Arcuri F, Brucoli M, Grivetto F, Benech A. Mandibular symphyseal fracture simulated by a foreign body in the chin. *J Craniofac Surg*. 2012;23:e91-e93.
27. Brucoli M, Stecco A, Iaquina C, Carriero A, Benech A. Diagnosis and treatment of orbit posttraumatic subperiosteal hemorrhage in a child, associated with a subdural intracranial hemorrhage. *J Craniofac Surg*. 2005;16:407-410.
28. Saponaro A, Stecco A, Brucoli M, et al. Magnetic resonance imaging in the postsurgical evaluation of patients with mandibular condyle fractures treated using the transparotid approach: our experience. *J Oral Maxillofac Surg*. 2009;67:1815-1820.

Reprint requests:

Matteo Brucoli
Division of Maxillofacial Surgery
University of Eastern Piedmont
Corso Mazzini 18
Novara 28100
Italy
mattbrucoli@gmail.com