



Available online at  
**ScienceDirect**  
[www.sciencedirect.com](http://www.sciencedirect.com)

Elsevier Masson France  
**EM|consulte**  
[www.em-consulte.com/en](http://www.em-consulte.com/en)



Original article

# Efficacy of local glucocorticoid after local anesthetic in low back pain with lumbosacral transitional vertebra: A randomized placebo-controlled double-blind trial



Joëlle Glémarec<sup>a,\*</sup>, Stéphane Varin<sup>b</sup>, Céline Cozic<sup>b</sup>, Gilles Tanguy<sup>b</sup>, Christelle Volteau<sup>c</sup>, Philippe Montigny<sup>d</sup>, Benoît Le Goff<sup>a</sup>, Christelle Darrietort Laffite<sup>a</sup>, Yves Maugars<sup>a</sup>, Grégoire Cormier<sup>b</sup>

<sup>a</sup> Service de rhumatologie, CHU Hôtel-Dieu, 1, place Alexis-Ricordeau, 44000 Nantes, France

<sup>b</sup> Service de rhumatologie, CHD Vendée, boulevard S.-Moreau, 85925 La Roche-sur-Yon cedex 9, France

<sup>c</sup> Cellule de promotion de la recherche clinique, Cap ouest, 44000 Nantes, France

<sup>d</sup> Service d'imagerie médicale, CHD Vendée, boulevard S.-Moreau, 85925 La Roche-sur-Yon cedex 9, France

## ARTICLE INFO

### Article history:

Accepted 15 March 2017  
 Available online 8 May 2017

### Keywords:

Lumbosacral transitional vertebra  
 Bertolotti syndrome  
 Local injection

## ABSTRACT

**Objective:** The primary objective of this study was to compare the efficacy of local injection of a local anesthetic with a glucocorticoid versus a local anesthetic with saline to treat low back pain due to lumbosacral transitional vertebrae (LSTV) with a pseudoarticulation.

**Methods:** A randomized placebo-controlled double-blind study was conducted in patients with unilateral low back pain ascribed clinically to LSTV. Patients were randomized to lidocaine plus saline (LS group) or lidocaine plus cortivazol (LC group) injected locally under computed tomography guidance. The primary outcome measure was the 24-hour mean visual analog scale (VAS) score for low back pain 4 weeks after the injection.

**Results:** Of 16 randomized patients, 15 were included in the analysis, 8 in the LS group and 7 in the LC group. The mean VAS pain score at week 4 was not significantly different between the two groups. In the two groups pooled, the mean VAS pain score decreased significantly from baseline to week 4, from  $5.52 \pm 0.99$  to  $3.86 \pm 2.55$  ( $P \leq 0.05$ ). The difference remained significant at week 12. Significant improvements occurred in the EIFEL disability index and items of the Dallas Pain Questionnaire. No adverse events were recorded.

**Conclusion:** In patients with chronic low back pain consistent with a symptomatic LSTV type II or IV in the Castellvi classification, a local injection of lidocaine with or without cortivazol may provide sustained improvements in pain and function. The underlying mechanism is unclear.

© 2017 Société française de rhumatologie. Published by Elsevier Masson SAS. All rights reserved.

## 1. Introduction

Lumbosacral transitional vertebrae (LSTV) are present in 5% to 35% of the general population [1–4]. Their role in low back pain has been debated for nearly a century. In 1917, Bertolotti reported the first case of low back pain in a patient with LSTV. Castellvi et al. [5] developed a classification in four types, with types II and IV (35% of cases) having a pseudoarticulation between the transverse process and sacrum on one or both sides (Fig. 1). Two studies found no increase in the frequency of low back pain among individuals with LSTV [1,6], whereas several others suggested an association

[7–11]. In a bone scintigraphy study, 81% (39/48) of the patients with low back pain and a type II LSTV had increased uptake at the pseudoarticulation [9]. Of 4636 participants in a cohort of peripheral osteoarthritis, 841 (18.1%) had LSTV, and the subgroup with type II or IV LSTV had a significantly increased prevalence of low back pain [10]. Similarly, in a population-based study of 5860 participants, types II and IV LSTV were significantly associated with low back pain and buttock pain (type II, odds ratio [OR]: 2.56 [95% CI, 2.17–3.89] for low back pain and 5.38 [95% CI, 4.29–8.43] for buttock pain; type IV, OR: 4.28 [95% CI, 3.21–6.35] for low back pain and 6.82 [95% CI, 5.17–16.59] for buttock pain) [11]. Few studies have assessed the management of low back pain in patients with LSTV.

We conducted a randomized, placebo-controlled, double-blind trial of cortivazol versus saline, combined with a local anesthetic,

\* Corresponding author.

E-mail address: [joelle.glemarec@chu-nantes.fr](mailto:joelle.glemarec@chu-nantes.fr) (J. Glémarec).

injected locally under computed tomography (CT) guidance to treat low back pain in patients with type II or IV LSTV.

## 2. Methods

### 2.1. Patients

Patients were recruited prospectively between June 2010 and December 2014. The planned sample size was 30 patients in each treatment arm.

#### 2.1.1. Inclusion criteria

Inclusion criteria were as follows:

- unilateral low back pain, on the side of the pseudoarticulation, for more than 3 months;
- mechanical pain in the distal lumbar spine or buttock, without sciatica (no pain below the knee);
- pain elicited by finger pressure over the pseudoarticulation;
- mean pain intensity over the past 24 hours greater than 4 on a 0–10 visual analog scale;
- pain unresponsive to the combined use of analgesics and a non-steroidal anti-inflammatory drug (NSAID);
- LSTV type IIa or IV in the Castellvi classification, with the pain on the side of the pseudoarticulation;
- no evidence by CT or magnetic resonance imaging (MRI) of another abnormality capable of generating the clinical symptoms.

#### 2.1.2. Exclusion criteria

Patients meeting any of the following criteria were excluded:

- age < 18 years;
- inability to comprehend the study protocol;
- pregnancy or possible pregnancy on the day of the injection;
- clinical evidence supporting disk disease as the source of the pain: triggering factor, pain exacerbation during coughing or straining, spinal syndrome, positive straight leg-raising test;
- patients unable to get around on their own;
- hypersensitivity to amide local anesthetics, porphyria, local or systemic infection, severe clotting disorder, current anticoagulant therapy;
- diabetes mellitus;
- bilateral low back pain and bilateral pseudoarticulation (Castellvi type IIb), which would hinder the efficacy assessment.

### 2.2. Conduct of the study

Randomization was achieved using TENALEA software (The Trans European Network, <http://www.tenalea.com>), with a block design and stratification on center. The rheumatologist and patient were blinded to the treatment group, although the radiologist was not. All injections were performed under CT guidance, by a radiologist who had extensive experience with interventional radiology. The treatments were as follows:

- lidocaine plus saline (LS group): 1 mL of 1% lidocaine followed immediately by 1.5 mL of saline;
- lidocaine plus cortivazol (LC group): 1 mL of 1% lidocaine followed immediately by cortivazol 1.5 mL.

The study rheumatologist assessed the effect of the local anesthetic 30 minutes after the injection by having the patient complete a 0–10 point visual analog scale (VAS) for pain. After 30 minutes, any decrease in pain can only be due to the anesthetic, as corticosteroids

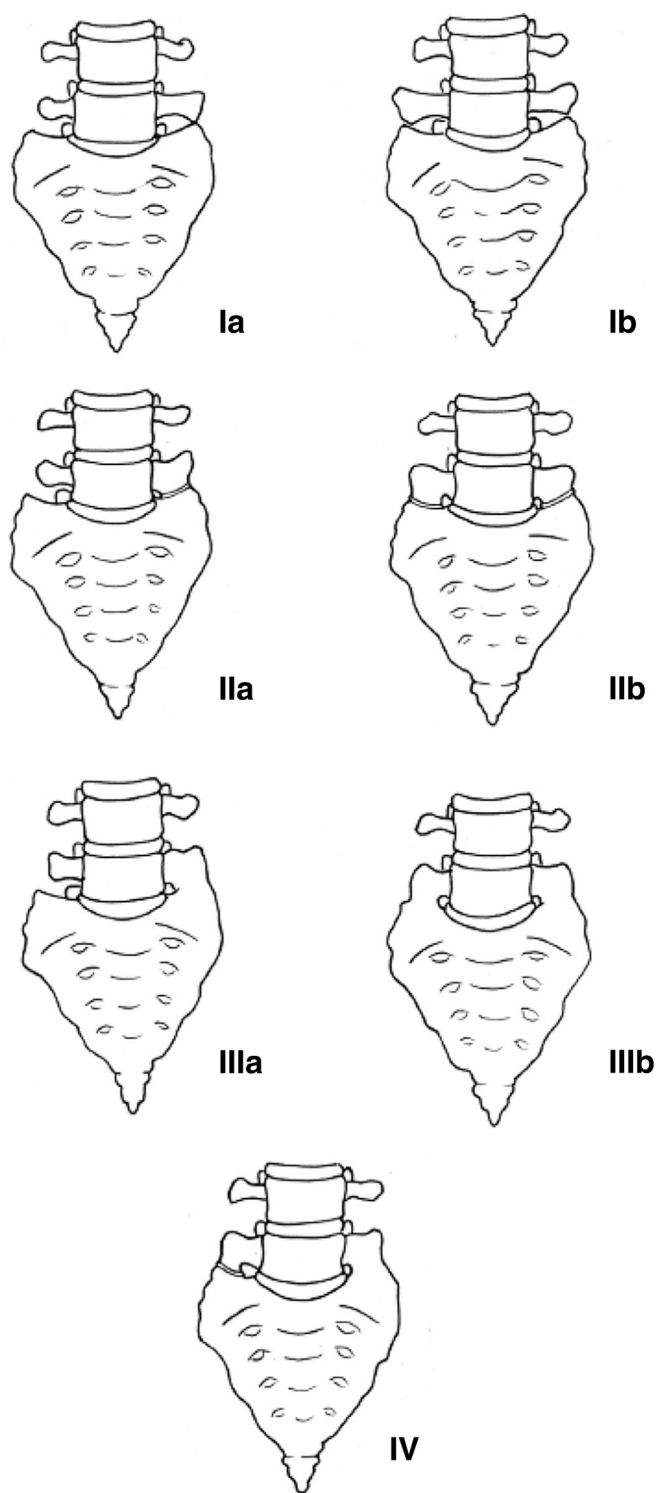


Fig. 1. Castellvi classification of lumbosacral transitional vertebrae.

have no immediate effects. A positive anesthetic test was defined as an at least 75% decrease in the VAS pain score. The same rheumatologist reevaluated the patient after 7 days, 4 weeks, and 12 weeks.

### 2.3. Evaluation criteria

The primary outcome measure was the change in the mean 24-hour VAS pain score from baseline to 4 weeks after the injection. The secondary outcome measures were as follows:

**Table 1**  
Baseline features in the lidocaine/saline (LS) and lidocaine/cortivazol (LC) groups and changes in visual analog scale (VAS) pain scores over time.

	LS group n = 8	LC group n = 7	Total n = 15	P value
Age, years, mean ± SD	43.7 ± 19.1	41.7 ± 11.8	42.8 ± 15.6	NS
Duration of low back pain, months, mean ± SD	46.7 ± 68.7	56.7 ± 53.6	51.3 ± 61.6	NS
Sick leave due to low back pain, yes/total	2/8	2/7	4/15	NS
Type of birth defect	8 type II	6 type II, 1 type IV	14 type II, 1 type IV	NS
VAS score at baseline, mean ± SD	5.44 ± 1.21	5.61 ± 0.76	5.52 ± 0.99	NS
VAS score on day 7, mean ± SD	4.85 ± 2.54	3.71 ± 2.56	4.32 ± 2.54	NS (change vs. baseline in the overall population)
VAS score at week 4, mean ± SD	4.11 ± 2.8	3.57 ± 2.42	3.86 ± 2.55	<0.05 (change vs. baseline in the overall population)
VAS score at week 12, mean ± SD	2.18 ± 2.17	4.43 ± 2.7	3.23 ± 2.62	<0.001 (change vs. baseline in the overall population)

**Table 2**  
Previously published data.

Author	Year	Study design	Number of patients	Medications injected locally	Positive anesthetic test
Avimadge et al. [15]	1999	Retrospective	11	Lidocaine + glucocorticoid	8
Marks and Thulbourne [14]	1991	Prospective	10	Lidocaine + glucocorticoid	8
Santavirta et al. [18]	1993	Open-label preoperative	6/16 operated patients	Lidocaine	6
Gepner et al. [16]	1995	Open-label preoperative (Abstract)	5	Lidocaine	5
Jonsson et al. [17]	1989	Open-label preoperative	10	Lidocaine	5 total, 4 partial

- percentage improvement as assessed by the patient and by the rheumatologist;
- improvements in the EIFEL score for low back pain disability and in the Dallas Pain Questionnaire score;
- return to work in the subgroup of patients who were of working age and on sick leave at the time of the injection;
- consumption of analgesics, NSAIDs, and co-analgesics.

After 12 weeks, patients with persistent pain could have their blind broken and those in the LS group offered an open-label cortivazol injection under CT guidance.

**3. Statistical analyses**

The statistical analyses were performed using SAS version 9.1 software (SAS, Cary, NC, USA). All tests were two-tailed, and P values < 0.05 were taken to indicate significant differences.

The primary outcome measure was the difference in the mean 24-hour VAS pain score from baseline to 4 weeks after the injection. The required sample size was estimated by assuming a VAS decrease of 1 point in the LS group and 3 points in the LC group, with a standard deviation of 2 in both groups [12]. To detect this difference with 90% power, with the α risk set at 5%, 30 patients were needed in each group, i.e., 60 patients in all. The non-parametric Wilcoxon test was chosen to compare the primary outcome between the two treatment groups.

Secondary outcome measures were compared using either the non-parametric Wilcoxon test or, for comparisons of baseline values to week 4 or week 12 values in the two treatment groups pooled, the Wilcoxon test for paired data.

**4. Results**

We were able to include only 16 patients. Among them, 1 was lost to follow-up after the injection, leaving 15 patients for the analysis, 7 in the LC group and 8 in the LS group. The two groups showed no significant differences at baseline (Table 1).

The lumbosacral junction was assessed by CT in 10 patients, MRI in 4 patients, and both in 1 patient. Of the 5 patients with MRI, none had high signal from the pseudoarticulation [13].

The primary outcome measure (VAS pain score change from baseline to 4 weeks) was not significantly different between the

two groups. Neither was the VAS pain score change from baseline to day 7 or week 12 significantly different between the two groups.

Compared to baseline, the VAS pain scores were significantly decreased at weeks 4 and 12 (Table 1).

Among secondary outcome measures, the anesthetic test was positive in 8 patients, 4 in each group. A positive anesthetic test did not correlate with the VAS pain score decrease at week 4. The number of patients with a greater than 50% VAS pain score decrease at week 4 was 7 overall, 4 in the LS group, and 3 in the LC group. Overall, the EIFEL disability score improved from 9.00 ± 5.24 at baseline to 5.53 ± 5.84 at week 12 (P < 0.01), with no difference between the two groups. Similarly, scores on the Dallas Pain Questionnaire sections improved overall, with no differences between groups. The data did not allow an assessment of potential treatment effects on medication consumption or work ability. No adverse effects were recorded.

**5. Discussion**

We were unable to enrol the required sample size, chiefly due to difficulties in establishing a link between the low back pain and the pseudoarticulation, as many patients also had facet joint or disk abnormalities by CT and/or MRI. We felt that selecting the patients based on an anesthetic block of the pseudoarticulation a few weeks before the study would be unacceptably cumbersome. In addition, some patients were unwilling to be randomized and asked for an open-label corticosteroid injection. Thus, of the patients screened for the study, only 30% were included. Despite our small sample, to our knowledge, this is the largest therapeutic trial to date of local injection therapy for low back pain with LSTV. Table 2 recapitulates the previous publications.

In the previous studies, fluoroscopy was used to guide the injection. In two studies, no true arthrography was obtained, and the contrast agent diffused out of the pseudoarticulation [14,15]. Bias due to injection site errors was eliminated in our study by the use of CT (Fig. 2a and b).

Only two studies assessed short-term and medium-term efficacy. In a prospective study of 10 patients with unspecified LSTV types, 9 patients experienced pain relief after the injection of a corticosteroid and local anesthetic, including 5 whose pain recurred at the same level after 1 day to 12 weeks, 3 with partial pain relief after 7 to 41 months, and 1 free from pain after 2 years [14]. The

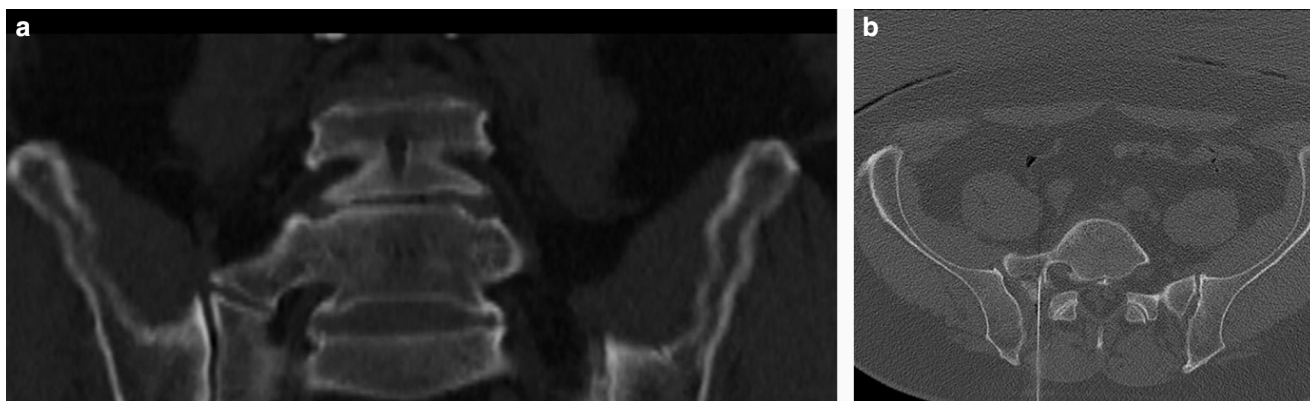


Fig. 2. a: identification of landmarks by computed tomography; b: injection under computed tomography guidance.

other efficacy study retrospectively included 11 patients with type II LSTV [15]. After 1 month, 9 patients had an at least 50% decrease in pain intensity. Among the 8 patients with data collected after 6 to 24 months, 2 were pain-free and 3 had a 50% decrease in pain intensity. A single patient experienced no pain relief at any time point. The other studies merely report the results of the preoperative anesthetic test, with no details [16–18]. Several studies assessed the outcomes of surgical treatment, which were usually good in recent years [19–21]. Finally, radiofrequency sensory ablation was used successfully in 1 patient [22].

The study objective was to determine whether a glucocorticoid was more effective than saline when injected into the pseudoarticulation immediately after a local anesthetic. The results show no difference in efficacy. A control group with no local injection would have been of interest to determine whether the improvement was due to the injection or merely to the natural history of the pain or to a placebo effect. Nevertheless, 60% (9/15) of the patients were improved at week 4. Furthermore, the pain relief was already apparent on day 7 (9/15) and persisted at week 12 (10/15). The prolonged pain relief in a single patient probably reflects the natural course of the pain. It should be borne in mind that the patients had chronic pain, with a mean duration of  $51.4 \pm 47.8$  months (range, 5–224 months). The persistence of the response over time therefore argues in favor of a therapeutic effect as opposed to spontaneous fluctuations in pain intensity or to a placebo effect. In the patients whose pain improved, the therapeutic effect included significant functional improvements, as assessed by the EIFEL and Dallas scores, with no significant differences between the two groups.

The improvement noted in the LS group may be ascribable to stretching of the capsule by the injection of saline combined with the anesthetic effect of saline on group C sensory nerve fibers [23]. In patients with chronic low back and nerve pain due to lumbar spinal stenosis, epidural adhesiolysis followed by hypertonic saline neurolysis proved effective [24]. The treatment failures in our study may indicate errors in patient selection, with the inclusion of patients whose pain originated from a disk, facet joint, or sacroiliac joint.

In patients with chronic pain ascribed to LSTV Castellvi type II or IV, i.e., with a pseudoarticulation, an injection of saline may have therapeutic effects. This finding deserves evaluation in a study involving multiple centers, in order to obtain a larger sample size.

#### Funding source

This study was funded by the association ANPIR, CHU Hotel dieu, 1, place Alexis Ricordeau, 44000 Nantes, France.

#### Disclosure of interest

The authors declare that they have no competing interest.

#### References

- [1] Tini PG, Wieser C, Zinn WM. The transitional vertebra of the lumbosacral spine: its radiological classification, incidence, prevalence and clinical significance. *Rheumatol Rehabil* 1977;16:180–5.
- [2] Delpont EG, Cucuezlla TR, Kim N, et al. Lumbosacral transitional vertebrae: incidence in a consecutive patient series. *Pain physician* 2006;9:53–6.
- [3] French HD, Somasundaram AJ, Schaefer NR, et al. Lumbosacral transitional vertebrae and its prevalence in the Australian population. *Global Spine J* 2014;4:229–32.
- [4] Paik NC, Lim CS, Jang HS. Numeric and morphological verification of lumbosacral segments in 8280 consecutive patients. *Spine (Phila Pa 1976)* 2013;38:E573–8.
- [5] Castellvi AE, Goldstein LA, Chan DP. Lumbosacral transitional vertebrae and their relationship with lumbar extradural defects. *Spine* 1984;9:493–5.
- [6] Yavuz U, Bayhan AI, Beng K, et al. Low back complaints worse, but not more frequent in subjects with congenital lumbosacral malformations: a study on 5000 recruits. *Acta Orthop Belg* 2012;78:668–71.
- [7] Peterson CK, Bolton J, Hsu W, et al. A cross sectional study comparing pain and disability levels in patients with low back pain with and without transitional lumbosacral vertebrae. *J Manipulative Physiol Ther* 2005;28:570–4.
- [8] Quilan JF, Duke D, Eustace S. Bertolotti's syndrome: a cause of back pain in young people. *J Bone Joint Surg Br* 2006;88:1183–6.
- [9] Connolly LP, D'Hemecourt PA, Connolly SA, et al. Skeletal scintigraphy of young patients with low back pain and a lumbosacral transitional vertebra. *J Nucl Med* 2003;44:909–14.
- [10] Nardo L, Alizai H, Virayavanich W, et al. Lumbosacral transitional vertebrae: association with low back pain. *Radiology* 2012;265:497–503.
- [11] Tang M, Yang XF, Yang SW, et al. Lumbosacral transitional vertebra in a population-based study of 5860 individuals: prevalence and relationship to low back pain. *Eur J Radiol* 2014;83:1679–82.
- [12] Cohen SP, Bogduk N, Dragovich A, et al. Randomized, double-blind, placebo-controlled, dose-response, and preclinical safety study of transforaminal epidural etanercept for the treatment of sciatica. *Anesthesiology* 2009;110:1116–26.
- [13] Neelakantan S, Anandarajan R, Shyam K, et al. Multimodality imaging in Bertolotti's syndrome: an important cause of low back pain in young adults. *BMJ Case Rep* 2016, <http://dx.doi.org/10.1136/bcr-2016-217121>.
- [14] Marks RC, Thulbourne T. Infiltration of anomalous lumbosacral articulations. Steroid and anesthetic injections in 10 back-pain patients. *Acta Orthop Scand* 1991;62:139–41.
- [15] Avimadje M, Goupille P, Jeannou J, et al. Néo-articulation transverso-sacrée ou transverso-iliaque et lombalgies. Étude rétrospective de 12 cas. *Rev Rhum [Ed Fr]* 1999;1:37–42.
- [16] Gepner P, Ppierron D, Robine D. Lombalgie chronique et vertèbre transitionnelle lombo-sacrée: un lien pathogénique probable. [résumé]. *Rev Rhum [Ed Fr]* 1995;62:736.
- [17] Jonsson B, Strömqvist B, Egund N. Anomalous lumbosacral articulations and low back pain. Evaluation and treatment. *Spine* 1989;14:831–4.
- [18] Santavirta S, Tallroth K, Ylinen P, et al. Surgical treatment of Bertolotti's syndrome: follow-up of 16 patients. *Arch Orthop Trauma Surg* 1993;112:82–7.
- [19] Ugokwe KT, Chen TL, Klineberg E. Minimally invasive surgical treatment of Bertolotti's syndrome: case report. *Neurosurgery* 2008;62:454–5.
- [20] Almeida DB, Mattei TA, Soria MG, et al. Transitional lumbosacral vertebrae and low back pain: diagnostic pitfalls and management of Bertolotti's syndrome. *Arq Neuropsiquiatr* 2009;67:268–72.

- [21] Li Y1, Lubelski D, Abdullah KG, et al. Minimally invasive tubular resection of the anomalous transverse process in patients with Bertolotti's syndrome: presented at the 2013 Joint Spine Section Meeting: clinical article. *J Neurosurg Spine* 2014;20:283–90.
- [22] Burnham R1. Radiofrequency sensory ablation as a treatment for symptomatic unilateral lumbosacral junction pseudo-articulation (Bertolotti's syndrome): a case report. *Pain Med* 2010;11:853–5.
- [23] Trescot AM, Chopra P, Abdi S, et al. Systematic review of effectiveness and complications of adhesiolysis in the management of chronic spinal pain. An update. *Pain Phys* 2007;10:129–46.
- [24] Manchikanti L, Rivera JJ, Pampati V, et al. One day lumbar epidural adhesiolysis and hypertonic saline neurolysis in treatment of chronic low back pain: a randomized double blind trial. *Pain Phys* 2004;7:177–86.