



Review

The use of laser Doppler flowmetry to evaluate oral soft tissue blood flow in humans: A review



Ayepa Alain Kouadio^{b,c}, Fabienne Jordana^b, N'goran Justin Koffi^c, Pierre Le Bars^{b,1},
Assem Soueidan^{a,*,1}

^a Department of Periodontology, UIC Odontology, Nantes Dental School 1, Place Alexis-Ricordeau, 44042 Nantes Cedex 1, France

^b Department of Prosthetic, UIC Odontology, Nantes Dental school 1, Place Alexis-Ricordeau, 44042 Nantes Cedex 1, France

^c UFR d'Odonto-stomatologie, Université Félix Houphouët Boigny, 22 BP 612 Abidjan 22, Cote d'Ivoire

ARTICLE INFO

Keywords:

Laser Doppler flowmetry

Oral mucosa

Gingival blood flow

ABSTRACT

The objective of this work is to define the conditions for improving the use of laser Doppler flowmetry (LDF) and to determine the limits for the use of this technique.

This article systematically reviews the literature on the evaluation of oral soft tissue blood microcirculation by LDF. We analysed the available literature through October 2016 using the database resources Medline/PubMed, the Cochrane Oral Health Group Specialist Trials Register and the ISI Web of Knowledge.

Several points emerged from this literature review

The use of LDF involves specific constraints; however, the influence of different factors (temperature, tobacco, pressure etc.) must be adequately controlled when using LDF. LDF measurements of soft tissue within the oral cavity vary depending on the anatomical site. In dentistry, LDF can be used to track healing progress in periodontal surgery and to diagnose vascular flow changes in the connective tissue of mucosae covered by a removable prosthesis at an early stage prior to the onset of clinical inflammation signs.

1. Introduction

LDF allows the measurement of microcirculation in tissues of humans and animals. This approach was first used in the 1980s and continues to be used because it is not invasive and is an easy technique to use after a training period. The principle of LDF is based on light-tissue interactions, i.e., the principle of the Doppler effect as applied to laser radiation (Doppler, 1842) (Fig. 1). The main disadvantage of LDF is that it does not accurately measure blood flow, so it cannot be used to calculate absolute blood flow (e.g., in units of ml/min/100 g tissue). LDF produces a relative value of blood flow (Vongsavan & Matthews, 1993). This technique has been used for various tissues such as skin (Svalestad, Hellem, Vaagbø, Irgens, & Thorsen, 2010), retina (Riva, Geiser, & Petrig, 2010), intestine (Hoff, Gregersen, & Hatlebakk, 2009), kidney (Babos, Járαι, & Nemcsik, 2013) and bone (Hellem, Jacobsson, Nilsson, & Lewis, 1983). In addition, in the orofacial area (Retzepi, Tonetti, & Donos, 2007a; Verdonck et al., 2009), this tool has been used to highlight the microcirculation of the tongue (Singh, Stansby, & Harrison, 2008), the buccal mucosa (Hirai, 2005), periodontal tissue

(Cho, Yu, Lee, Lee, & Kim, 2013), the masseter muscle (Curtis, Gansky, & Plesh, 2012), human dental pulp (Gazelius, Olgart, Edwall, & Edwall, 1986; Chen & Abbott, 2009) and luxated teeth (Gazelius, Olgart, & Edwall, 1988).

However, issues involving the use of this technique must be strictly respected, such as the method of standardization adopted for the Periflux, the effects of ambient light and the artefacts caused by probe movement during measurements (Vongsavan & Matthews, 1993). Therefore, in dentistry (Orekhova & Barmasheva, 2013), the study of blood microcirculation in various soft tissues is used to evaluate the following:

- The mucosal variation of microcirculation due to pathological conditions in the oral cavity (gingivitis, periodontitis, white and red lesions)
- The healing of gingival, palatal and connective grafts
- Tissue modification in mucosa recovery due to dentures

This article systematically reviews the literature on the use of LDF

* Corresponding author.

E-mail addresses: ayepa.Kouadio@univ-nantes.fr (A.A. Kouadio), fabienne-Jordana@univ-nantes.fr (F. Jordana), koffingoran@yahoo.fr (N.J. Koffi), pierre.le-bars@univ-nantes.fr (P. Le Bars), assem-Soueidan@univ-nantes.fr (A. Soueidan).

¹ These authors contributed equally to the work.

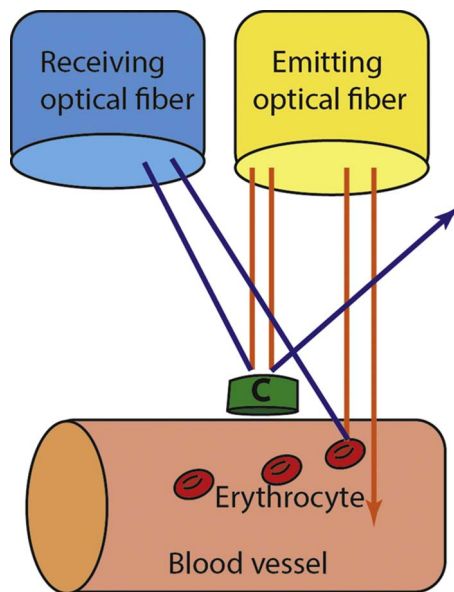


Fig. 1. Effect of Doppler applied to laser radiation; c: immobile cell.

for studying oral mucosa blood microcirculation.

2. Materials & methods

A literature search for articles published through October 31, 2016 was performed using the following keywords: “oral mucosa,” “palatal mucosa,” “alveolar mucosa,” “mucosa gingival,” “laser Doppler flowmetry” and “laser Doppler”. Combinations of the keywords were also used. A total of 295 articles were extracted from PubMed/MEDLINE; the Cochrane Oral Health Group (COHG) Specialist Trials Register and ISI Web of Knowledge. Article titles and abstracts were examined to exclude irrelevant articles and articles that had already been manually identified. Then; the abstracts of the selected articles were read to identify studies that met the inclusion criteria. Finally; additional articles were obtained by reviewing the references of the selected articles.

2.1. Inclusion criteria

Original articles written in English were included in the review if they met one of the following criteria:

- Articles on blood microcirculation in the human oral cavity mucosa measured using laser Doppler

- Articles on the measurement of microcirculation in the human oral cavity mucosa using laser Doppler
- Articles on the variability of blood microcirculation in the oral cavity mucosa measured using laser Doppler

2.2. Exclusion criteria

- Articles were excluded from this review if they met one of the following criteria:
- Articles on blood microcirculation in the oral cavity of animals measured using laser Doppler
- Articles on blood microcirculation in the oral mucosa of animals measured using laser Doppler
- Articles on blood microcirculation in dental organs measured using laser Doppler (indirect measurement)
- Clinical case reports (due to the high variability of the results)
- Articles written in a language other than English.

The articles were divided into five themes to provide a precise clinical perspective in this review. The following themes were analysed:

1. Recording techniques used with LDF
2. Stimuli that can modify blood flow
3. Oral cavity soft tissues that are studied with LDF
4. LDF applications in surgical treatments
5. The influence of mucosal recovery on a removable prosthesis

3. Results

The electronic and manual literature searches resulted in 295 articles. After evaluating the titles and abstracts, the references from the selected articles, and the exclusion and inclusion criteria, 30 articles were chosen and read entirely (Fig. 2).

To summarize our results, the papers were grouped according to five themes as follows:

1. Recording techniques used with LDF (Table 1) (Hoke, Burkes, White, Duffy, & Klitzman, 1994; Hinrichs, LaBelle, & Aeppli, 1995; Matsuki, Xu, and Nagasawa, 2001; Singh et al., 2008)
2. Stimuli that can modify blood flow (Table 2) (Baab, Oberg, & Holloway, 1986; Herlofson, Brodin, & Aars, 1996; Ahn & Pogrel, 1998; Ketabi & Hirsch, 1997; Perry, McDowell, & Goodis, 1997; Heckmann et al., 2000; Kempainen, Avellan, Handwerker, & Forster, 2003; Patino-Marin et al., 2005; Sakr et al., 2010; Kawai et al., 2013); (Reuther, Hale, Matharu, Blythe, & Brennan, 2016)
3. Oral cavity soft tissues that are studied with LDF (Table 3) (Baab, Oberg, & Lundström, 1990; Matheny, Johnson, & Roth, 1993; Matheny,




Fig. 2. Selection procedure of articles included in the literature review.

Table 1
Influences of parameters and technics with probe for measuring oral soft tissues blood flow (BF) using laser Doppler. Variability of the results is showed by Hoke et al. (1994) and Singh et al. (2008) in relation with different sites. Matsuki et al. (2001) shows the influence of the position of the probe (angulation and distance). Hinrichs et al. (1995) shows no difference between manual and fixed probes.

Study	METHODS			RESULTS	
	Specificity	Laser Doppler	Location and probe	Number of sites/number of measures per sites/time	Soft tissues
Hoke et al. (1994) USA	14 Healthy	Laserflow BPM 403 laser Doppler flowmeter TSI, Inc, St Paul, MN, USA	Oral mucosa Comparison between flows measured with A handheld probe and with a stent stabilized probe	18/3/30s	There were no statistically significant differences between hand-held and stent-stabilized probes.
Hinrichs et al. (1995) USA	9 Healthy	Laserflow, Model 403A, Vasamedics inc, St. Paul, MN USA	Gingival sulci Comparison between flows measured with stents stabilized and non-stents stabilized	5/2/1 month interval	For the same sites the differences of measures for both stent stabilized and hand held method were statistically significant.**
Matsuki et al. (2001) Japan	5 Healthy	Advanced Company Ltd. Tokyo, Japan	Labial gingiva of upper central incisor comparison between flows measured with different distance and angle for probe	2/2/1 day interval	When changing the probe distance from 1 to 10 mm, the blood flow rate become smaller, but was not statistically significant effect from the angle.
Singh et al. (2008) UK	10 Healthy	Moor Instruments DRT4	Tongue and oral mucosa Comparison between flows measured with surface probe and catheter endoscopic probe	10/ND/at 0H,6H and 24 h	The measurements using the surface probe were significantly higher than with the endoscopic probe at all times and sites*

* P < 0,05.

Abrams, Johnson, & Roth, 1993; Heckmann et al., 2001; Kerdvongbundit, Vongsavan, Soo-Ampon, Phankosol, & Hasegawa, 2002; Kerdvongbundit, Sirirat, Sirikulsathean, Kasetsuwan, & Hasegawa, 2002; Kerdvongbundit, Vongsavan, Soo-Ampon, & Hasegawa, 2003; Svalestad, Thorsen, Vaagbø, & Hellem, 2014; Le Bars et al., 2016)

4. The application of LDF in surgical treatments (Table 4) (Ambrosini, Cherene, Miller, Weissenbach, & Penaud, 2002; Donos, D’Aiuto, Retzepi, & Tonetti, 2005; Retzepi et al., 2007a; Retzepi et al., 2007b)

5. The influence of mucosal recovery on a removable prosthesis (Table 5) (Akazawa & Sakurai, 2002; Kocabalkan & Turgut, 2005; Okada, Ueda, & Sakurai, 2010); (Ogino, Ueda, Ogami, Koike, & Sakurai, 2017)

4. Discussion

LDF is a useful, non-invasive, sensitive, reproducible, and non-harmful method that is used to measure blood flow in soft tissues in humans (Stern, 1975; Oberg, Tenland, & Nilsson, 1984).

LDF can reduce the use of objective and unreliable sensitivity tests (Gazelius et al., 1986; Ebihara, Tokita, Izawa, & Suda, 1996; Evans, Reid, Strang, & Stirrups, 1999; Emshoff, Moschen, & Strobl, 2004). Unlike molecular and cell biology techniques, LDF is non-invasive. LDF is a good tool for the diagnosis and follow-up of the progression/healing of gingivitis/periodontitis and for the evaluation of wound healing (Retzepi et al., 2007a; Retzepi, Tonetti, & Donos, 2007b).

An early and accurate assessment of blood flow is a significant asset in any physiopathological or treatment paradigm. Furthermore, the evaluation of wound healing can be significantly improved without the risks of contamination, infection or discomfort to the patient (Broz et al., 2015).

The disadvantages of LDF derive from uncontrolled micro-movements of the hand holding the probe, the pressure applied by the operator on the tissue, the angle of the probe, (Hinrichs et al., 1995; Hoke et al., 1994; Vongsavan and Matthews, 1993) which inevitably differs from assessment to assessment, and the unknown morphology of the vasculature. Laser Doppler flowmetry is also spatially limited (1 mm³) (Frerichs & Feuerstein, 1990; Rajan, Varghese, van Leeuwen, & Steenbergen, 2009). It should be emphasized that Laser Doppler is not very easy technique, time consuming and requires some experience. In addition, the relatively high cost of this type of apparatus in a private practice must be taken into account (Roeykens, Deschepper, & De Moor, 2016). We will detail the different parameters that can influence the measurement technique with laser Doppler first, and then we will define the use of this technique in the field of periodontal surgery and in mucosa under dentures.

4.1. The influence of various parameters and techniques on measurements of oral soft tissue blood flow with laser doppler (Table 1)

Based on the reviewed literature, several factors must be controlled, especially those concerning the optical probe.

4.1.1. The optical probe

The reliability of measurements depends on probe stabilization. However, according to Hoke, the results do not depend on whether the flow rates are measured with a handheld probe, with a stabilized probe on the attached gingiva or with a stabilized adhesive probe on the back of the hand (Hoke et al., 1994). In contrast, a study by Hinrichs et al. (1995) noted several coefficients that significantly differ depending on whether LDF is performed with a stabilized probe or a non-stabilized probe. Higher correlation coefficients were found when using a stabilized probe.

Two other parameters include the distance from the probe tip to the tissue and the angle of the probe. According to Matsuki et al. (2001), a

Table 2

Oral soft tissues blood flow (BF) measured by laser Doppler after different stimulations. Many stimulations increase BF like: tobacco (Baab et al., 1986), anesthetic (vasodilatation) (Kempainen et al., 2003), Sedative and anesthetic agent (dexmedetomidine) Kawaai et al. (2013), Sodium lauryl sulphate (SLS) (Herlofson et al., 1996), dry ice (Heckmann et al., 2000), Tooth brushing (Perry et al., 1997), heat (Baab et al., 1986). While other stimulation like: local anesthetic (vasoconstriction) (Ketabi and Hirsch, 1997; Ahn and Pogrel, 1998); pressure; occlusal force (Baab et al. (1986)); compression (Patino-Marin et al., 2005) decreased BF. The surgical stress induces redistribution of microvascular in buccal mucosa blood flow (Sakr et al., 2010). Electronic cigarettes (vape) containing nicotine can have an effect on the blood flow at the level of the buccal mucosa (Reuther et al., 2016).

Study	METHODS				Results
	Specificity	Laser Doppler	Probe location	Stimuli	
Baab et al. (1986) USA	10 Healthy young adults	Periflux PF1d, Perimed KB, Stockholm, Sweden	- interdental papillae - free gingiva - attached gingiva - alveolar mucosa	- heat (water flush, 44 °C) - cold (water flush, 15 °C) - pressure (1.5N, 60 s) - occlusal force: patient bite firmly on a wooden wedge for 15 s	Soft tissues (stimuli influencing the blow flow) No significant differences in mean BF between the stimuli (heat or cold) No significant differences among tissues types after release of pressure. Significant difference with occlusal biting force (F = 5N) was seen between tissues. ^{**}
Baab and Oberg (1987) Usa	12 Healthy young smoker volunteers	Periflux PF-2, Perimed, Stockholm, Sweden	Buccal sulcus of tooth n°26	Tobacco	Significantly higher GBF during smoking and 5 min after; than that seen during sham smoking Significantly high heart rate with smoking over sham smoking
Herlofson et al. (1996) Norway	14 Healthy adults (1 smoker)	Periflux PF2b. Perimed, Sweden	Bilaterally 3 mm above the gingival margin, between the central and lateral maxillary incisors	Sodium lauryl sulphate (1.5%)	With sodium lauryl sulphate, average gingival LDF values increased significantly compared with the control side from the second to tenth min.
Ahn and Pogrel (1998) Usa	10 Volunteers	Periflux PF3, Perimed, Stockholm, Sweden	Gingival margin of an asymptomatic upper first premolar	Local anesthetic (lidocaine, 2%) with adrenaline (1:100,000)	After lidocaine injection, significant reduction from baseline values in GBF (maximum decrease: 51%) and a gradual return toward the baseline value within 35 min *
Ketabi and Hirsch (1997) Australia	- 20 non-smokers - 20 smokers	Periflux 2b, Perimed AB, Stockholm, Sweden	Gingival surface of the papilla between upper left central and lateral incisors	local anesthetic (lignocaine, 2%) with adrenaline (1:80,000)	Injection of lignocaine resulted in a marked and significant drop (average: 46%, sd: 13.5) in the LDF from gingiva. The recovery of LDF signals to baseline took considerably longer in smokers than in non-smokers, This difference was statistically significant. ^{***} Tooth brushing for both 3 and 10 s significantly increased gingival blood flow in the papillary gingiva of healthy individuals.
Perry et al. (1997) Usa	20 Healthy adults	Model MBF3/D, Moor Instruments, Devon, UK	The mesial papillae of 6 teeth	Tooth brushing: - for 3 s - for 10 s	Mucosal BF increased Significantly at all sites in response to application of dry ice with peak flow at 0.5 min to 1.5 min after onset of stimulation. ^{***}
Heckmann et al. (2000) Germany	26 Healthy	Periflux 4001 Master; Perimed, Stockholm, Sweden	- hard palate - tip of the tongue - midline or the oral vestibule - at the lip	Dry ice pen (CO ₂)	Mucosal BF increased Significantly at all sites in response to application of dry ice with peak flow at 0.5 min to 1.5 min after onset of stimulation. ^{***}
Kempainen et al. (2003) Finland	7 Trained healthy	Periflux PF2B, Perimed AB, Stockholm, Sweden	Attached gingiva or alveolar mucosa between teeth 11/12 or teeth 21/22	Capsaicin (3%) – unilateral application	Capsaicin stimuli, planned comparison showed that tooth stimulation induced a significantly higher flow response during the stimulation period and 3 min after stimulation.

(continued on next page)

Table 2 (continued)

Study	METHODS				Results
	Specificity	Laser Doppler	Probe location	Stimuli	
Patino-Marin et al. (2005) Mexico	20 Healthy	PF 5001 main unit + PF 5010 LDPM unit, Perimed AB, Stockholm, Sweden	labial lower left	compression with a wood-mounted cotton swab until the perfusion	Soft tissues (stimuli influencing the blow flow) The compression significantly reduced gingival perfusion to almost 1/5 of its control value, showing a recuperation to control phase levels 9 s after compression was released.*
Sakr et al. (2010) Germany	20 Healthy	O2C, Lea Medizintechnik GmbH, Giesen, Germany	lateral incisor attached gingiva	decreased to about 1/5 of its control perfusion value	Three experimental sessions, with interval of one week Baseline: 40 s Recording: 40 s
Kawaai et al. (2013) Japan	8 Patients admitted for monitoring after surgery 21 Patient within 24 h of the onset of septic shock		Buccal mucosa	septic shock	Twice Measurements: every 2 s for 5 min For non-septic patients, buccal mucosa flow was significantly greater superficially* and lower deeply compared with healthy volunteers.*** Superficial mucosa BF increased during the second day of septic shock in survivors and decreased thereafter.
Reuther et al. (2016) Uk	13 Healthy	ALF21R, Advance, Tokyo	Comparison between measured for non-septic and septic shock patients - superficial (2 mm) - deep (6 mm) Palatal mucosa of the upper first molar buccal mucosa	Comparison between measured for non-septic and septic shock patients - superficial (2 mm) - deep (6 mm) Palatal mucosa of the upper first molar buccal mucosa	2: the second after at least 1 week Recording: at 0, 5, 10, 12, 22, 32 min after 5 min of vaping Recording: intervals at 5 min intervals for 30 min
	10 Healthy	the moorVMS-LDF2, Moor Instruments, Axminster, Devon, UK		dexmedetomidine (Sedative) with intravenous catheter electronic cigarettes (of which half contained nicotine and half did not) (vape)	The palatal mucosal BF decreased significantly after the start of the infusion of dexmedetomidine.*** A significant difference between the electronic cigarettes that contained nicotine and those that did not.*

BF: Blood flow
GBF: Gingival blow flow
* P < 0, 05.
** P < 0,01.
*** P < 0,001.

Table 3

Oral soft tissues blood flow (BF) measured by laser Doppler (healthy and inflamed gingiva). First article show the influence of temperature between healthy and juvenile periodontitis (Baab et al., 1990). Second paper studied the change in the gingival microcirculation during the development of experimental gingivitis in humans by Matheny and Johnson et al. (1993). Third paper show the influence of age on the marginal gingival blood flow by Matheny and Abrams et al. (1993). Fourth paper explains the effect of dry ice on burning mouth syndrome for decrease BF (Heckmann et al., 2000). The five paper show the statistically significant variability of BF between different sites of maxillary and mandibular mucosa Kerdvongbundit and Vongsavan et al. (2002), Kerdvongbundit and Sirirat et al. (2002). The sixth and seventh paper obvious the increase of base flow from healthy mucosa to periodontitis by Kerdvongbundit and Vongsavan et al. (2002), Kerdvongbundit and Sirirat et al. (2002) (Kerdvongbundit et al. (2003). The next paper demonstrated the efficacy of HBOT in irradiated patient for increase the BF (Svaltestad et al., 2014). Last paper show the sensitivity of laser Doppler for measuring the microcirculation of the palatal mucosa, assessing the median raphe (MR), Schroeder area (SA), and retroincisive papilla (RP) by Le Bars et al. (2016).

Study	Methods			Results	
	Specificity	Laser Doppler	Probe location	Number of sites/ Measures recording/ Number of measures per site	Soft tissues (healthy and inflamed gingiva)
Baab et al. (1990) Usa	10 with a history of periodontit	Periflux PF-2, Perimed	gingival sulcus on the buccal of tooth No. 26	1	-Patients with localized juvenile periodontitis and progressive periodontitis had similar rewarming temperature curves, but significantly faster BF recovery curves than controls.
Matheny and Johnson et al. (1993), Usa	10 healthy 10 Health	TSI, Inc., St. Paul, MN	Gingiva of upper anterior teeth	Baseline: 5 min Recording: -3 min of cooling to 19 °C -12 min of rewarming Twice 1	- Significant decrease in gingival regional BF was seen with gingivitis.
Matheny and Johnson et al. (1993). Usa	20 Young group, healthy non-smokers	TSI, Inc., St. Paul, MN	Marginal gingiva of the upper anterior teeth	Recording: 5 min (2 visits) 2 1	-Volume of flow in the marginal gingiva increased slightly with age, while velocity decreased with age, although neither of these changes were statistically significant.
Heckmann et al. (2001) Germany	20 Middle age group, healthy non-smokers 20 Old group, healthy non-smokers 13 Burning mouth syndrome (BMS)	Perifux 4001 Master, Perimed, Stockholm, Sweden	hard palate, tip of the tongue, midline of the oral vestibule, and on the lip	Records during 5 min 1 4	-MBF increased significantly at all measurement sites in response to dry ice application. -The vasoactivity in BMS patients was higher than in healthy controls. BMS patients exhibited a higher significantly response on the hard palate compared to controls.
Kerdvongbundit and Vongsavan et al. (2002), Thailande	13 healthy non-smoking controls matched for age and gender	Moor Instruments, Axminster, England	gingival surface, between the right and left of the maxillary and mandibular canines	Baseline: 30 s Measurements: over 2 min 1 for the burning mouth syndrome patients Twice on 2 consecutive days, for the control group 20	-Maxillary aMBF measurement at each site in the anterior gingiva showed significant differences. - MBF in the mandibular anterior gingival region, only the alveolar mucosa showed a significant difference of BF from that in the other sites. -MBF in the maxillary anterior gingiva showed significant differences from that in the mandibular anterior gingiva in the interdental gingiva, attached gingiva, and alveolar mucosa. -BF measurements with in the same group demonstrated significant differences at every site.
Kerdvongbundit and Vongsavan et al. (2002), Thailande	42 Healthy non-smokers	Moor Instruments, Axminster, England	gingival surface between the right and left of the maxillary canines	Baseline: least 15 min, Recording: 90-s intervals. 20	-BF in patients with moderate gingivitis and periodontitis revealed significant differences when compared with that in the healthy gingiva at all sites examined.
	20 Healthy non-smokers moderate gingivitis 20 Healthy non-smokers periodontitis	Moor Instruments, Axminster, England	gingival surface between the right and left of the maxillary canines	Baseline: least 15 min, or Recording: 90-s intervals.	

(continued on next page)

Table 3 (continued)

Study	Methods	Specificity	Laser Doppler	Probe location	Number of sites/ Measures recording/ Number of measures per site	Results
Kertvongbundit et al. (2003) Thailande	12 Healthy non-smokers clinically healthy gingiva	Moor Instruments, Axminster, England	gingival surface between the right and left maxillary canines	20	-Periodontal status in the gingivitis group differed significantly from that in the healthy gingiva group, both before treatment and 1 and 3 months after gingivitis treatment.* -BF before treatment in the gingivitis group was significantly different from that in healthy gingiva, and there were also significant differences between the groups 1 and 3 months after treatment, at all sites.**	
Svaalestad et al. (2014) Norway	22 Patients formerly treated for head and neck cancer by hyperbaric oxygen therapy (HBOT)	Perimed AB, Järfälla, Sweden	at least 5 mm away from the gingival sulcus or dental papilla	1	-After HBOT BF in mucosa and skin after heat provocation increased significantly.*	
Le Bars et al. (2016) France	54 healthy participants (12 smokers)	PeriFlux System 5000; Perimed, Sweden	Palatal mucosa: median raphe (MR), Schroeder area (SA), and retroincisive papilla (RP).	Baseline: 10 min to allow for stabilization Recording: 10 min 3: baseline, after 3 months, after 6 months 3	-TCPO2 (transcutaneous oximetry) increased significantly in the irradiated cheek, but not at reference points outside the field of radiation.* - Palatal MBF differed significantly among the anatomical areas.* -The mean value of SA was significantly higher than the RP* which in turn was higher than that of RM. ^{***}	
				Baseline: least 5 min Recording: 3 min 1		

BF: Blood flow; Mucosal blood flow (MBF)

Table 4
 Oral soft tissues blood flow (BF) measured by laser Doppler (therapeutics), show the periosteal stimulation induces statistically significant increases in the BF (Ambrosini et al., 2002). The second study, the LDF might present clinical applicability in recording changes in gingival BF following periodontal surgery (Donos et al., 2005). In the third paper, the topographically distinct areas of the periodontal access flap consistently present different patterns of microvascular BF alterations during the wound healing period (Retzeppi et al., 2007a). The four article show, the simplified papilla preservation flap may be associated with faster recovery of the gingival BF post-operatively compared with the modified Widman flap (Retzeppi et al., 2007b).

Study	Methods				Results	
	Specificity	Laser Doppler	Probe location	Therapeutics	Number of sites Measures recording Number of measures per site	Soft tissues (Therapeutics influencing the blow flow)
Ambrosini et al. (2002) France	13 healthy	PF2B, Perimed, Sweden	Surface of the gingival graft.	Periosteal stimulation after gingival graft	24 just before stimulation and 8 days after Initial trial to verify reproductibility	After a gingival graft, the patient who has underwent periosteal stimulation showed a statistically significant increase the GBF even after a week.
Donos et al. (2005) Uk	5 Patients referred for treatment of chronic generalized severe periodontitis. (2 smokers, 3 non-smokers)	5010 Periflux, Perimed AB, Jarfalla, Sweden	Alveolar mucosa, papillae, palatal and buccal mucosa	Periodontal surgery with gingival flap	40	-After gingival flap, the GBF presented an overall increase in comparison to baseline values until the 7th day following surgery at all of the sites. -By the 15th day, as well as at the following observation periods of 30 and 60 days, the GBF values at the palatal and alveolar mucosa sites were very similar to baseline (0). -Only increased blood flow changes were observed at 30 and 60 days following operation at the buccal interdental sites.
Retzeppi et al. (2007a) Uk	14 Patients referred for the treatment of chronic generalized periodontitis.	5010 Periflux, Perimed, Jarfalla, Sweden	- mucosal flap basis - buccal papillary - palatal papillary	Periodontal access flap surgery	9 Baseline: day of the surgery, prior to local anesthesia. Recording: (3 min following anesthesia, immediately after the operation and at days 1, 2, 3, 4, 7, 15, 30 and 60)	- Significant ischaemia was observed at all flap sites following anesthesia and immediately postoperatively. -At the alveolar mucosal sites, a peak statistically significant show increase of the GBF was, observed on postoperative day 1 ^{***} , which persisted until day 7 [*] and resolved by day 15. -The mucosal sites close to the flap periphery presented higher blood perfusion compared with the sites located centrally in the flap. (no statistically significant) -The microcirculatory perfusion of the buccal [*] and palatal papillae ^{***} was maximum on postoperative day 7 and returned to baseline by day 15.
Retzeppi et al. (2007b) Uk	10 Patients referred for the treatment of chronic generalized periodontitis	5010 Periflux, Perimed, Jarfalla, Sweden	- mucosal flap basis - buccal papillary - palatal papillary	- the simplified papilla preservation flap (SPPF) -Periodontal access flap surgery: modified Widman flap (MWF)	20 Baseline: day of the surgery, prior to local anesthesia. Recording: (same of [*])	-Significant peak increase above the baseline was observed on day 7 at the palatal papillae of both groups and returned to baseline by day 15. - Both surgical modalities (SPPF) and (MWF) yielded significant pocket depth reduction, recession increase and clinical attachment gain

GBF: Gingival blow flow

Table 5
 Oral soft tissues blood flow (BF) measured by laser Doppler for denture wearers. The first paper show that the number of simulated chewing strokes had no influence on mean BF during intermittent loading in denture-supporting mucosa (Akazawa & Sakurai, 2002). In the second paper, it appears that wearing dentures hinders BF to denture supporting tissues, even when soft liners are used (Kocabalkan and Turgut, 2005). Whatever the duration and frequency of the load, the mean blood flow of the palatal mucosa under a removable prosthesis is greater than before stimulation (Okada et al., 2010). The last paper concluded that slow chewing induced less blood flow than typical or fast chewing in denture-supporting mucosa (Ogino et al., 2017).

Study	Methods			Stimuli	Measures recording Number of measures per site	Results
	Specificity	Laser Doppler	Probe location			
Akazawa and Sakurai (2002) Japan	8 Denture wearers (removable partial dentures): absence of the mandibular first molar tooth	Flowmeter ALF21, Advance, Tokyo, Japan	The buccal area on the alveolar crest of the mandibular first molar site	Loading force: 10 N. Loading time was set for 5, 10, 20, 30 and 60 s at random	Recording: 5, 10, 20, 30 and 60 s	-The BF in the denture underlying mucosa showed that there was a statistically significant correlation between the recovery time and the loading time.**
Kocabalkan and Turgut, (2005) Turkey	20 Mandibular denture wearers (removable complete dentures: 10 hard bases and 10 soft bases)	Periflux 4001, Master Perimed	Bilaterally, in the canine and molar regions	-only denture supporting by underlying mucosa	Baseline: before denture wearing. Recording: 1 week, 1 month, 3 months and 6 months All records are made after 15 min	For hard acrylic resin and soft lining: Mean BF to the mucosa after 1 week was significantly lower in the measured regions than that obtained before the dentures were worn.* -Return in normality after 6 months for both bases in the canine region -However, BF in the molar region of the denture with the hard base group increased after 6 months in comparison to initially recorded values. -statistically significant difference was observed in mean blood flow between at pre-loading and all loading durations.*
Okada et al. (2010) Japan	11 dentate adults, no visible palatal mucosa abnormalities	Flowmeter ALF21, Advance, Tokyo, Japan	Hard palate	Loading force: intermittent forces (10N, 1/0.75 Hz)	Baseline: at rest, at which time blood flow was considered to be at equilibrium. Recording: 1, 4, 8, 12 min. One measurement per day.	-Blood flow was higher than at pre-loading for all intermittent loading durations
Ogino et al. (2017) Japan	20 healthy dentulous men	ALF21; Advance, Tokyo, Japan	palatal mucosa	Loading time: for 1, 4, 8, 12 min (80, 320, 640 or 960 chewing strokes) Loading pressure: presse manual at 10 N (5 N/cm ²)	Baseline: more than 10 s (steady blood flow) Recording: after conditions of simulated clenching or simulated chewing for 30 s. 8 conditions (sufficient intervals between each measurement)	-significant correlation between the amount of blood flow during simulated chewing and the extent of reactive hyperaemia.

BF: Blood flow

distance of less than or equal to 3 mm ensures reliable measurements of gingival blood flow. Furthermore, according to the same authors, perpendicular orientation of the probe to the tissue surface improves measurement reliability.

In addition, LDF can be used in combination with other methods, including visible light spectrophotometry (VLS), which measures visible light.

4.1.2. Laser doppler and visible light spectrophotometry (VLS)

A previous study compared the results of LDF (Moor Instruments DRT4) and measurements of tissue oxygen saturation (SO₂) by VLS (Whitland Research RM200) in the tongue and oral mucosa. Regarding probe inter-variability, the results indicated that the SO₂ measurements by VLS using various probes on the tongue and mucosa were significantly correlated. Blood flow measurements obtained using various probes were significantly correlated, but the standard deviations were very large. Furthermore, the results revealed that the SO₂ measurements were not correlated with the LDF results (Singh et al., 2008). However, the two methods were not comparable because one measures blood flow and the other measures oxygen saturation. VLS is a clinical tool that is easily used to measure tissue ischaemia. Combining LDF and VLS can be useful in the management of patients who are in intensive care due to septic shock from surgery. Indeed, LDF superficially measures the oral mucosa microcirculation, while VLS provides a more detailed measurement of haemoglobin oxygen saturation (μHbO₂) (Sakr et al., 2010).

4.2. The measurement of oral soft tissue blood flow by laser doppler after various types of stimulation (Table 2)

4.2.1. Tobacco

The complex effect of tobacco on the blood microcirculation in the buccal area includes many parameters. The use of LDF has revealed the following features:

Historically, vasoconstriction was found to be initiated by the action of nicotine on noradrenaline secretion (Shuler, 1968). The study by Baab and Oberg (1987) on the effect of smoking on gingival blood flow (GBF) showed that smoking causes a transient increase in GBF that returns to the original level after 10 min. According to these authors and contrary to popular belief, it appears that smoking does not reduce gingival blood flow in humans. Another parameter tested by Ketabi and Hirsch (1997) supported this result. Indeed, the use of a local anesthetic (lignocaine hydrochloride 2% (0.5 ml) with adrenaline 1:80,000) in the gums of smokers resulted in an initial decrease in gingival blood flow that later returned to baseline levels compared with non-smokers.

However, two effects must be distinguished: heat-induced vasodilation (Molnár et al. 2015) and nicotine-induced vasoconstriction; these two contradictory effects interact with each other. Nevertheless, the high dose of nicotine absorbed by chronic smokers may exert the dominant effect (Svalestad et al., 2010). Another study using laser Doppler measurements used a heat test as a valuable tool to examine the vascular reactivity of gingival vessels (Molnár et al. 2015). Another parameter is the frequency of smoking. Assessing blood pressure control, Mavropoulos (Mavropoulos, Aars, & Brodin, 2003) used the laser Doppler technique and detected a hyperaemic response in casual smokers due to an increase in blood pressure, and the net result was slight vasoconstriction. In three groups (light smokers, heavy smokers and non-smokers), (Meekin, Wilson, Scott, Ide, & Palmer, 2000) evaluated gingival blood flow using laser Doppler and found no acute effect of smoking on gingival blood flow. This finding could be due to the absence of a comparison of the baseline values among the groups and to the fact that blood pressure was not measured. The findings of another study (Morozumi, Kubota, Sato, Okuda, & Yoshie, 2004) may explain this result; gingival blood flow as measured by laser Doppler was elevated in former smokers after smoking cessation.

Reuther et al. (2016) suggested that the use of electronic cigarettes

for smoking cessation should not be ignored or dismissed, which could at least serve as a short-term measure via laser Doppler, and that these devices may even have some beneficial effects, although their long-term safety remains unknown.

Finally, the results obtained using LDF can be influenced by the presence of periodontal disease in smokers. (Marcenes et al., 2013) explained that periodontal inflammation can change the morphological aspects of the gingiva and can modify gingival blood flow. The results of smokers depend on the severity of periodontal disease. In the case of moderate periodontal inflammation, Molnár et al. (2015) showed that vascular modification could be suppressed by smoking.

4.2.2. Vasoconstrictors and vasodilators

The vasoconstrictive effects of two local anaesthetics, 2% lidocaine with adrenaline 1:100,000 (Ahn & Pogrel, 1998) and dexmedetomidine, an α₂ adrenoceptor agonist (Kawaai et al., 2013), on gingival mucosa flow and on palatal mucosa were evaluated. Both resulted in a significant decrease in blood flow. The vasodilator effect of capsaicin (Capsaicin 3%, 10 ml), when applied topically to the alveolar mucosa and to the attached gingiva, has been highlighted by laser Doppler imaging (LDI), which measures microcirculation and blood perfusion. The results of blood flow measurements revealed that the alveolar mucosa is more sensitive than the attached gingiva to chemical irritants, such as capsaicin (Kemppainen et al., 2003). These results were corroborated in five different studies, four of which concerned the surgical treatment of periodontal disease (Ambrosini et al., 2002; Donos et al., 2005; Retzepe et al., 2007a; Retzepe et al., 2007b) (see part 4, Oral soft tissue blood flow measured by laser Doppler) and the technique used to record blood flow with LDF (Hinrichs et al., 1995) (see part 1). The authors used adrenaline Alphacaine 2%, Xylocaine at a dose of 3.6 ml and 1.8 ml of 2% lidocaine with adrenaline 1:80,000, and 0.2 to 0.3 ml of 2% lidocaine with 1:100,000 adrenaline (Ambrosini et al., 2002; Donos et al., 2005; Hinrichs et al., 1995; Retzepe et al., 2007a; Retzepe et al., 2007b).

It appears advisable for practitioners to use adrenaline for gingival retraction without any concern regarding side effects. A low concentration of 0.01% may prevent both hyperaemia and the production of crevicular fluid in the marginal gingiva after cord removal without affecting systemic circulatory parameters or causing prolonged ischaemia (Csillag, Nyiri, Vag, & Fazekas, 2007).

4.2.3. Temperature

Topical temperature changes on the oral mucosa were tested to measure blood flow fluctuations. First, in a study by Heckmann, the application of dry ice (CO₂) for 10 s (Heckmann et al., 2000) resulted in increased mucosal blood flow at various sites in the oral cavity (the tongue, palatal mucosa, lip and vestibule); this increase reached a maximum at 30 s and returned to the baseline level at 90 s after stimulation. Overall, the responses in elderly patients were more variable than those observed in younger patients. Stimulation with dry ice appears to be an effective, non-invasive and tolerable method for studying blood microcirculation at different mucosal sites.

Therefore, the evaluation of mucosal blood flow appears to be a promising tool for studying the pathophysiology of neurological symptoms. Furthermore, in the study by Baab et al. (1986), the application of water at 15 °C or 44 °C under the oral mucosa caused transient hyperaemia, which was followed by a rapid return to the initial blood flow level after the cessation of stimulation. More recently, another study with laser Doppler measurements used the heat test with a halogen lamp and demonstrated that an elevation in temperature caused a rapid significant and transient increase in GBF in the human gingiva (Molnár et al., 2015).

4.2.4. Compression

Several authors have studied the influence of pressure on buccal areas using LDF. (Patino-Marin et al., 2005) noted a transient decrease

in gingival blood flow following compression applied with a cotton swab on the alveolar mucosa. (Baab et al., 1986) tested another method based on a spring device that demonstrated the onset of ischaemia followed by hyperaemia for all types of tissues after applying a localized pressure of 1.5 N. The same authors studied the influence of an occlusal force applied to mandibular and maxillary central incisors and described transient ischaemia in the free gingiva, while blood flow remained unchanged at the interdental papillae and the attached gingiva of the tested teeth.

4.2.5. Brushing and toothpaste

Some authors have studied whether daily hygiene techniques influence mucosal blood flow using LDF. Perry et al. (1997) noted an increase in microcirculation in healthy gingival mucosa after brushing for short durations (3 s and 10 s) using a nylon multi-tooth soft brush. Regarding toothpaste, Herlofson et al. (1996) tested the effect of sodium lauryl sulphate (1.5%, applied for 90 s), a detergent that is widely used in toothpaste. The GBF measured above the marginal gingiva of the maxillary incisors was increased between the second and tenth minutes and reached a maximum at eight minutes before returning to baseline levels.

4.2.6. Septic shock

The measurement of buccal microvascular responses in patients with septic shock using combined laser Doppler flowmetry/visual light spectroscopy shows a buccal mucosal response to surgical stress that is consistent with a redistribution of microvascular flow in favour of superficial layers (Sakr et al., 2010).

4.3. Oral soft tissue blood flow measured using the laser doppler technique (healthy and inflamed gingiva) (Table 3)

The oral mucosa is divided into several areas that are related to underlying muscle or bone structures. Depending on the topography of the oral cavity, the oral mucosa is divided into the masticatory mucosa, the bordering mucosa and the specialized area (back of the tongue).

Blood microcirculation differs between these buccal mucosa areas.

4.3.1. Healthy and inflamed gingiva

Blood microcirculation in healthy gingiva was studied in the maxillary and mandibular areas using LDF by Kerdvongbundit's team (Kerdvongbundit and Sirirat et al., 2002; Kerdvongbundit and Vongsavan et al., 2002). The results indicated that blood circulation in the anterior maxillary gingiva was significantly higher than that in the anterior mandibular gingiva. This finding was also true for the interdental gingiva, the attached gingiva and the alveolar mucosa. It was also noted that the bone tissue density was significantly higher in the mandible than in the maxilla. On the other hand, blood microcirculation measurements confirmed that the anterior maxilla responded more favourably to surgery (tissue sampling, grafting, periodontal decontamination, etc.) than the anterior mandible. Therefore, healthy gingiva has low blood flow, and inflammatory processes appear to increase blood flow. Studying the palatal mucosa, Le Bars et al. (2016) showed that the Schroeder area appeared to have the greatest sensitivity and that vascular flow variability among individuals was greatest in this region. These findings suggest that the analysis of blood stream changes using laser Doppler measurements of the palatal mucosa can help detect the onset of pathological alterations.

In 2003, the same team (Kerdvongbundit, Vongsavan, Soo-Ampon, & Hasegawa, 2003) measured the amount of time required for inflamed gingiva to recover a healthy appearance after a hygiene treatment. LDF for blood microcirculation, coupled with scanning electron microscopy (SEM) to examine gum micromorphology, demonstrated that the inflamed gingiva returned to normal within three months. Matheny and Abrams et al. (1993); Matheny and Johnson et al. (1993), who created an experimental model of gingivitis in humans by suspending oral

hygiene for 12–16 days, assessed changes in the gum microcirculation. By combining LDF with videomicroscopy, the researchers showed a significant decrease in blood flow in the presence of gingivitis. We propose a possible explanation for the different results observed between gingivitis and periodontitis, namely, the greater spatial limit of LDF. Although periodontitis proceeding from the gingiva to the bone (through the periodontium) can span a 1-cm anatomical area, the flowmeter can measure only an area of $\sim 1 \text{ mm}^2$.

This protocol reveals a dramatic and dynamic change in gingival microcirculation in response to the establishment of gingivitis and its progression.

Other studies have also shown that the marginal gingiva mandibular area has a higher rate of blood flow than the maxillary area according to LDF imaging (Kerémi et al., 2000); however, no difference in blood flow was detected in cases of periodontitis (Molnar et al., 2015).

4.3.2. Periodontitis and temperature

Baab et al. (1990) examined the effect of a fresh air current (15 °C) on the GBF of young patients with a history of localized juvenile periodontitis or progressive periodontitis using LDF. According to this study, inflamed gingiva react to fresh air by becoming warmer. This study further showed that patients with periodontitis and localized juvenile periodontitis have similar warming temperature curves but that the blood flow recovery curves are faster than those of control patients. Thus, GBF in periodontitis patients recovered faster after local cooling than that in healthy controls.

4.3.3. The influence of hyperbaric oxygen therapy on the microcirculation of irradiated patients

In 2013, Svalestad et al. (2014) conducted a study on patients with a history of radiotherapy of the orofacial region (50–70 Gy) with a follow-up period between 2 and 20 years. Using LDF, the authors measured blood flow after transcutaneous oximetry (TCPO₂) following hyperbaric oxygen therapy (OHB) (240 kPa). According to the study, blood flow in the mucosa and skin was significantly increased. In addition, TCPO₂ values were significantly increased in the irradiated cheek but did not reach reference point levels outside the radiation field. However, in the control group, no significant change in blood flow or TCPO₂ was observed. The results of this study revealed that the oxygenation and vascular capacity of irradiated facial skin and the gingival mucosa are enhanced by OHB.

4.3.4. Burning mouth syndrome (BMS)

In a previous study, Heckmann et al. (2001) measured oral mucosa blood flow using LDF in the presence of burning mouth syndrome (BMS). Measurements were conducted after applying dry ice for 10 s using a pen-like device (Vitstab w, dental Jaschke, Umkirch, Germany; diameter, 4 mm; dry weight, 10.8 g). The results demonstrated that mucosal blood flow increased in all areas in response to the application of dry ice, with flow reaching a maximum at 0.5–1.5 min and exhibiting a tendency to return to baseline after 2 min. The vasoreactivity of BMS patients was higher than that of healthy subjects. These changes in oral blood flow appear to be specifically related to symptoms that indicate disturbed vasoreactivity in the presence of BMS (Svalestad et al., 2010).

4.4. Oral soft tissue blood flow measured by laser doppler: modification of gingival blood flow by periosteal stimulation before a gingival graft (Table 4)

The survival of a gingival graft is dependent on the blood supply to the graft. Ambrosini et al. (2002) studied the effect of periosteal stimulation on GBF. Using periosteal stimulation before a gingival graft led to a statistically significant increase in GBF.

4.4.1. Change in blood flow in a periodontal flap

LDF also has applications in the field of periodontal surgery, including flaps. Donos (Donos et al., 2005) observed a change in blood

circulation in a flap using LDF. The author noted an increase in GBF for 7 days after surgery, followed by a gradual return to baseline after 60 days. This result was confirmed by [Retzeppi et al. \(2007a\)](#), [Retzeppi et al. \(2007b\)](#). It was also noted that GBF in the portion of the flap attached to the mucosa was more important than GBF in the central part of the flap. This finding extends a comparison of the Widman flap and a flap preserving the interdental papilla: in the latter, GBF recovers to the initial level of vascularization more quickly.

On the one hand, during healing, the morphology of a wound/flap changes. Therefore, it would be better to accommodate the altered condition instead of mechanically positioning the probe on the same location relative to the teeth, rather than relative to the flap or wound margin. On the other hand, to obtain reliable results, the researchers used a Periflux laser Doppler flow meter (Perimed, Stockholm, Sweden), so it was necessary to immobilize the laser Doppler probe during measurement. In the study of [Baab et al. \(1986\)](#), stents that perforated self-curing acrylics were used to support the laser Doppler probe. The stents were based on the lower anterior teeth and were 4–6 mm thick. The mucosa was 0.5 mm thick and was supported by an interposition installed wax structure during stent manufacture. Several studies have used this method to explore palate vascularization ([Heckmann et al., 2000](#)). In other studies, laser Doppler was used to measure the microcirculation of the palatal mucosa. For reliability, the immobility of the laser Doppler probe was maintained using a thermoformed channel with a pierced stud at each recording site ([Le Bars et al., 2016](#)).

4.5. Oral soft tissue blood flow measured by laser doppler in denture wearers (Table 5)

Table 5 highlights the advantages of using LDF to diagnose changes in mucosal microvascularization under a removable prosthesis. The influence of masticatory forces (10 N, 1/0.75 Hz) during different periods (T = 1, 4, 8 or 12 min) on the palatal mucosa blood flow (2 cm²) of eleven maxillary full denture wearers was studied by [Okada et al. \(2010\)](#) using LDF. In this study, three subjects showed no increase in blood flow during the application of masticatory pressure, while eight subjects showed a significant and steady increase in blood flow during stimulation compared to baseline. Chewing acted as a pump on blood circulation. The duration of the masticatory forces did not significantly affect blood microcirculation; however, the recovery time appeared to increase as the duration of stimulation increased.

The relationship between blood flow in denture-supporting mucosa during fast and slow chewing was studied by [Ogino et al. \(2017\)](#). The authors concluded that slow chewing induced less blood flow than typical or fast chewing in denture-supporting mucosa and that people with less reactive hyperaemia experienced less blood flow in denture-supporting mucosa during chewing. This same observation was already established by the results of [Akazawa & Sakurai \(2002\)](#) experiments. These authors used a continuous compression force of 10 N and performed measurements of mucosal blood flow near the mandibular first molar (2 cm²) in relation to a partial removable prosthesis every 5, 10, 20, 30 and 60 s. Early during the application of pressure, blood flow decreased. Upon removing the pressure, a return to baseline by more than 100% (110%) was observed. This high score can be explained by the viscoelastic properties of the palatal mucosa as evidenced by the study of [Kydd et al. \(1971\)](#).

A study [Kocabalkan and Turgut \(2005\)](#) examined the influence of materials based on hard and soft polymerized acrylic resins on mucosal blood flow before and after the delivery of a complete mandibular denture (1 week, 1 month, 3 months and 6 months). In this protocol, blood flow was measured bilaterally in the molar and canine regions using LDF. After one week, blood flow in the canine and molar regions was significantly lower than before dentures were worn in two different study populations (removable hard denture wearers and removable soft denture wearers). After six months, the blood flow in the canine areas

of those wearing removable hard dentures returned to near normal levels. However, the blood flow in the molar area increased. For removable soft denture wearers, the blood flow did not return to the levels recorded before insertion. Therefore, it appears that wearing a full mandibular denture impedes the flow of blood in supporting tissues, even when soft bases are used.

4.5.1. New perspectives for LDF

Many technical studies of microcirculation are currently available, and more studies are in development. These experiments have led to progress in the understanding of the pathogenesis of microvascular and tissue diseases. The techniques described here are not invasive and are currently allowed in the clinic. An innovative flow meter can measure the microcirculation not only at a single point alone but also over large surface areas.

Description of the Perimed system: The PIM PeriScan system is a laser Doppler imager used to noninvasively view perfusion in superficial tissues and variations in blood perfusion.

This technique can be used to study and monitor microcirculatory activity in healthy and diseased tissue. The PIM3 PeriScan system allows practitioners to highlight basic values and resulting microvascular responses to stimulation. Based on the Doppler principle, it is possible to view blood perfusion in two dimensions (Picture Mode) or over time (Monitoring Mode). The ease of operation and the simplicity of the software (LDPIwin) facilitate the interpretation of the results and the creation of the final study report. Laser beam scanning can be used to study very poorly perfused areas. No physical contact with the tissue is required and no tracer or dye is used. Therefore, the influence of this technique is minimal ([Hirai, 2005](#); [Bay, Hiliges, Weidner, & Sandborgh-Englund, 2009](#)).

Quantitative imaging of the microcirculatory blood supply to tissues improves the diagnosis, therapy and monitoring of vascular and critical diseases. Two microcirculation parameters, blood flow (blood volume per unit time in the vasculature) and perfusion (blood volume per volume tissue per unit time) are intimately related to blood flow velocity due to the morphology of the vasculature, vessel diameter and vessel density. Research using a modified microcirculation imager (integrated sidestream dark field – laser speckle contrast imaging (SDF-LSCI) in vitro and in vivo revealed quantitative measures of flow velocity and vasculature morphology (vessel diameters and vessel density).

Vessel diameter and vessel density can be estimated from the obtained images, allowing the quantitative mapping of flow and velocity and the estimation of tissue perfusion using laser speckle flowmetry. Therefore, the clinical realization of quantitative speckle flowmetry requires an estimation of blood vessel geometry. These findings demonstrate the quantitative flowmetry capabilities of LSCI and show that the clinically relevant parameters of blood flow, velocity and tissue perfusion can be quantitatively represented in SDF-LSCI microcirculation images ([Nadort, Kalkman, van Leeuwen, & Faber, 2016](#)).

5. Conclusions

The LDF technique has been used for approximately thirty years in many medical fields, and the technique has been greatly improved. Its use requires a mastery of the technique.

Recommendations for the use of laser Doppler flowmetry concern the probe used, the use of a splint, the duration of measurement, and the skill of the practitioner.

- Concerning the probe, [Setzer, Challagulla, Kataoka, and Trope, 2013](#) recommend limiting micro-movements of the hand and that the recording probes be used with a “silicone splint”, leading to a measurement discrepancy of 0.25%. In addition, this method limits the variation of the angle of hand holding.

- The use of a splint limits the subjective and unreliable pressure applied by the dentist and discrepancies in orientation, both in the sagittal and axial planes. The orientation of the shaft drilled in the

splint is influenced by the position of the area of the palate; therefore, it is better to use the same splint and shaft for different measurements in one patient.

– The duration of measurements should be noted (approximately 7 min for a tooth but only 5 min for soft tissue) and the time of day should be consistent (diurnal variations occur due to circadian rhythms) (Roeykens et al., 2016).

– The practitioner must be trained to minimum standards in the use of LDF, thus providing homogenous parameters for clinical measurements.

In dentistry, many applications of LDF involving soft tissue investigation are becoming more apparent.

However, several parameters can influence measurements of microcirculation using LDF (e.g., temperature, tobacco use, anesthesia use, brushing, and pressure), which must be addressed.

Histological knowledge of the most sensitive anatomical sites for measurements of microcirculation determines the best investigative information available using LDF. Despite the limitations of this technique and considering all these parameters, we suggest the use of LDF preferentially in two areas of dental practice: periodontal surgery and the monitoring of tissue reactions under dentures.

Conflict of interest

None.

References

- Ahn, J., & Pogrel, M. A. (1998). The effects of 2% lidocaine with 1:100,000 epinephrine on pulpal and gingival blood flow. *Oral Surgery, Oral Medicine, Oral Pathology, Oral Radiology*, 85(2), 197–202.
- Akazawa, H., & Sakurai, K. (2002). Changes of blood flow in the mucosa underlying a mandibular denture following pressure assumed as a result of light clenching. *Journal of Oral Rehabilitation*, 29(4), 336–340.
- Ambrosini, P., Cherene, S., Miller, N., Weissenbach, M., & Penaud, J. (2002). A laser Doppler study of gingival blood flow variations following periosteal stimulation. *Journal of Clinical Periodontology*, 29(2), 103–107.
- Baab, D. A., & Oberg, P. A. (1987). The effect of cigarette smoking on gingival blood flow in humans. *Journal of Clinical Periodontology*, 14(7), 418–424.
- Baab, D. A., Oberg, P. A., & Holloway, G. A. (1986). Gingival blood flow measured with a laser Doppler flowmeter. *Journal of Periodontal Research*, 21(1), 73–85.
- Baab, D. A., Oberg, A., & Lundström, A. (1990). Gingival blood flow and temperature changes in young humans with a history of periodontitis. *Archives of Oral Biology*, 35(2), 95–101.
- Babos, L., Járjai, Z., & Nemcsik, J. (2013). Evaluation of microvascular reactivity with laser Doppler flowmetry in chronic kidney disease. *World Journal of Nephrology*, 2(3), 77–83.
- Bay, B., Hiliges, M., Weidner, C., & Sandborgh-Englund, G. (2009). Response of human oral mucosa and skin to histamine provocation: Laser Doppler perfusion imaging discloses differences in the nociceptive nervous system. *Acta Odontologica Scandinavica*, 67(2), 99–105.
- Broz, P., Aschwanden, M., Partovi, S., Schulte, A. C., Benz, D., Takes, M., et al. (2015). Assessment of cutaneous microcirculation in unaffected skin regions by transcutaneous oxygen saturation monitoring and Laser Doppler flowmetry in systemic sclerosis. *Clinical Hemorheology and Microcirculation*, 60(3), 263–271.
- Chen, E., & Abbott, P. V. (2009). Dental pulp testing: A review. *International Journal of Dentistry*, 2009, 365785.
- Cho, K. H., Yu, S. K., Lee, M. H., Lee, D. S., & Kim, H. J. (2013). Histological assessment of the palatal mucosa and greater palatine artery with reference to subepithelial connective tissue grafting. *Anatomy & Cell Biology*, 46(3), 171–176.
- Csillag, M., Nyiri, G., Vag, J., & Fazekas, A. (2007). Dose-related effects of epinephrine on human gingival blood flow and crevicular fluid production used as a soaking solution for chemo-mechanical tissue retraction. *Journal of Prosthetic Dentistry*, 97(1), 6–11.
- Curtis, D. A., Gansky, S. A., & Plesh, O. (2012). Deep and superficial masseter muscle blood flow in women. *Journal of Prosthodontics*, 21(6), 472–477.
- Donos, N., D'Aluio, F., Retzeppi, M., & Tonetti, M. (2005). Evaluation of gingival blood flow by the use of laser Doppler flowmetry following periodontal surgery. A pilot study. *Journal of Periodontal Research*, 40(2), 129–137.
- Doppler, J. C. (1842). On the colored light of the double stars and certain other stars of the heavens. *Prague: Royal Bohemian Society of Sciences*.
- Ebihara, A., Tokita, Y., Izawa, T., & Suda, H. (1996). Pulpal blood flow assessed by laser Doppler flowmetry in a tooth with a horizontal root fracture. *Oral Surgery, Oral Medicine, Oral Pathology, Oral Radiology, and Endodontics*, 81(2), 229–233.
- Emshoff, R., Moschen, I., & Strobl, H. (2004). Use of laser Doppler flowmetry to predict vitality of luxated or avulsed permanent teeth. *Oral Surgery, Oral Medicine, Oral Pathology, Oral Radiology, and Endodontics*, 98(6), 750–755.
- Evans, D., Reid, J., Strang, R., & Stirrups, D. (1999). A comparison of laser Doppler flowmetry with other methods of assessing the vitality of traumatized anterior teeth. *Endodontics & Dental Traumatology*, 15(6), 284–290.
- Frerichs, K. U., & Feuerstein, G. Z. (1990). Laser-Doppler flowmetry. A review of its application for measuring cerebral and spinal cord blood flow. *Molecular and Chemical Neuropathology*, 12(1), 55–70.
- Gazelius, B., Olgart, L., Edwall, B., & Edwall, L. (1986). Non-invasive recording of blood flow in human dental pulp. *Endodontics & Dental Traumatology*, 2(5), 219–221.
- Gazelius, B., Olgart, L., & Edwall, B. (1988). Restored vitality in luxated teeth assessed by laser Doppler flowmeter. *Endodontics & Dental Traumatology*, 4(6), 265–268.
- Heckmann, J. G., Hilz, M. J., Hummel, T., Popp, M., Marthol, H., Neundörfer, B., et al. (2000). Oral mucosal blood flow following dry ice stimulation in humans. *Clinical Autonomic Research*, 10(5), 317–321.
- Heckmann, S. M., Heckmann, J. G., Hilz, M. J., Popp, M., Marthol, H., Neundörfer, B., et al. (2001). Oral mucosal blood flow in patients with burning mouth syndrome. *Pain*, 90(3), 281–286.
- Hellem, S., Jacobsson, L. S., Nilsson, G. E., & Lewis, D. H. (1983). Measurement of microvascular blood flow in cancellous bone using laser Doppler flowmetry and 133Xe-clearance. *International Journal of Oral Surgery*, 12(3), 165–177.
- Herlofson, B. B., Brodin, P., & Aars, H. (1996). Increased human gingival blood flow induced by sodium lauryl sulfate. *Journal of Clinical Periodontology*, 23(11), 1004–1007.
- Hinrichs, J. E., LaBelle, L. L., & Aepli, D. (1995). An evaluation of laser Doppler readings obtained from human gingival sulci. *Journal of Periodontology*, 66(3), 171–176.
- Hirai, H. (2005). Application of a laser Doppler perfusion imaging Periscan PIM II for measuring the blood flow of the oral mucosa. *Nihon Hotetsu Shika Gakkai Zasshi*, 49(1), 26–35.
- Hoff, D. A., Gregersen, H., & Hatlebakk, J. G. (2009). Mucosal blood flow measurements using laser Doppler perfusion monitoring. *World Journal of Gastroenterology*, 15(2), 198–203.
- Hoke, J. A., Burkes, E. J., White, J. T., Duffy, M. B., & Klitzman, B. (1994). Blood-flow mapping of oral tissues by laser Doppler flowmetry. *International Journal of Oral and Maxillofacial Surgery*, 23(5), 312–315.
- Kawaai, H., Yoshida, K., Tanaka, E., Togami, K., Tada, H., Ganzberg, S., et al. (2013). Dexmedetomidine decreases the oral mucosal blood flow. *British Journal of Oral and Maxillofacial Surgery*, 51(8), 928–931.
- Kempainen, P., Avellan, N. L., Handwerker, H. O., & Forster, C. (2003). Differences between tooth stimulation and capsaicin-induced neurogenic vasodilatation in human gingiva. *Journal of Dental Research*, 82(4), 303–307.
- Kerémi, B., Csempesz, F., Vág, J., Györfi, A., & Fazekas, A. (2000). Blood flow in marginal gingiva as measured with laser Doppler flowmetry. *Fogorvosi Szemle*, 93(6), 163–168.
- Kerdvongbundit, V., Sirirat, M., Sirikulsathean, A., Kasetsuwan, J., & Hasegawa, A. (2002). Blood flow and human periodontal status. *Odontology*, 90(1), 52–56.
- Kerdvongbundit, V., Vongsavan, N., Soo-Ampon, S., Phankosol, P., & Hasegawa, A. (2002). Microcirculation of the healthy human gingiva. *Odontology*, 90(1), 48–51.
- Kerdvongbundit, V., Vongsavan, N., Soo-Ampon, S., & Hasegawa, A. (2003). Microcirculation and micromorphology of healthy and inflamed gingivae. *Odontology*, 91(1), 19–25.
- Ketabi, M., & Hirsch, R. S. (1997). The effects of local anesthetic containing adrenaline on gingival blood flow in smokers and non-smokers. *Journal of Clinical Periodontology*, 24(12), 888–892.
- Kocbalkan, E., & Turgut, M. (2005). Variation in blood flow of supporting tissue during use of mandibular complete dentures with hard acrylic resin base and soft relining: A preliminary study. *The International Journal of Prosthodontics*, 18(3), 210–213.
- Kydd, W. L., Daly, C. H., & Wheeler, J. B., III (1971). The thickness measurement of masticatory mucosa in vivo. *International Dental Journal*, 21(4), 430.
- Le Bars, P., Niagha, G., Kouadio, A. A., Demoersman, J., Roy, E., Armengol, V., et al. (2016). Pilot study of laser doppler measurement of flow variability in the micro-circulation of the palatal mucosa. *BioMed Research International*, 2016, 5749150.
- Marcenes, W., Kassebaum, N. J., Bernabé, E., Flaxman, A., Naghavi, M., Lopez, A., et al. (2013). Global burden of oral conditions in 1990–2010: A systematic analysis. *Journal of Dental Research*, 92(7), 592–597.
- Matheny, J. L., Abrams, H., Johnson, D. T., & Roth, G. I. (1993). Microcirculatory dynamics in experimental human gingivitis. *Journal of Clinical Periodontology*, 20(8), 578–583.
- Matheny, J. L., Johnson, D. T., & Roth, G. I. (1993). Aging and microcirculatory dynamics in human gingiva. *Journal of Clinical Periodontology*, 20(7), 471–475.
- Matsuki, M., Xu, Y. B., & Nagasawa, T. (2001). Gingival blood flow measurement with a non-contact laser flowmeter. *Journal of Oral Rehabilitation*, 28(7), 630–633.
- Mavropoulos, A., Aars, H., & Brodin, P. (2003). Hyperaemic response to cigarette smoking in healthy gingiva. *Journal of Clinical Periodontology*, 30(3), 214–221.
- Meekin, T. N., Wilson, R. F., Scott, D. A., Ide, M., & Palmer, R. M. (2000). Laser Doppler flowmeter measurement of relative gingival and forehead skin blood flow in light and heavy smokers during and after smoking. *Journal of Clinical Periodontology*, 27(4), 236–242.
- Molnár, E., Lohinai, Z., Demeter, A., Mikecs, B., Tóth, Z., & Vág, J. (2015). Assessment of heat provocation tests on the human gingiva: The effect of periodontal disease and smoking. *Acta Physiologica Hungarica*, 102(2), 176–188.
- Morozumi, T., Kubota, T., Sato, T., Okuda, K., & Yoshie, H. (2004). Smoking cessation increases gingival blood flow and gingival crevicular fluid. *Journal of Clinical Periodontology*, 31(4), 267–272.
- Nadort, A., Kalkman, K., van Leeuwen, T. G., & Faber, D. J. (2016). Quantitative blood flow velocity imaging using laser speckle flowmetry. *Scientific Reports*, 6, 25258.
- Oberg, P. A., Tenland, T., & Nilsson, G. E. (1984). Laser-Doppler flowmetry: a non-invasive and continuous method for blood flow evaluation in microvascular studies. *Acta Medica Scandinavica Supplementum*, 687, 17–24.
- Ogino, T., Ueda, T., Ogami, K., Koike, T., & Sakurai, K. (2017). Effects of chewing rate and

- reactive hyperemia on blood flow in denture-supporting mucosa during simulated chewing. *Journal of Prosthodontic Research*, 61(1), 54–60.
- Okada, C., Ueda, T., & Sakurai, K. (2010). Blood flow in denture-supporting maxillary mucosa in response to simulated mastication by loading. *Journal of Prosthodontic Research*, 54(4), 159–163.
- Orehkova, L. Y., & Barmasheva, A. (2013). Doppler flowmetry as a tool of predictive, preventive and personalised dentistry. *The EPMA Journal*, 4(1), 21.
- Patiño-Marín, N., Martínez, F., Loyola-Rodríguez, J. P., Tenorio-Govea, E., Brito-Orta, M. D., & Rodríguez-Martínez, M. (2005). A novel procedure for evaluating gingival perfusion status using laser-Doppler flowmetry. *Journal of Clinical Periodontology*, 32(3), 231–237.
- Perry, D. A., McDowell, J., & Goodis, H. E. (1997). Gingival microcirculation response to tooth brushing measured by laser Doppler flowmetry. *Journal of Periodontology*, 68(10), 990–995.
- Rajan, V., Varghese, B., van Leeuwen, T. G., & Steenbergen, W. (2009). Review of methodological developments in laser Doppler flowmetry. *Lasers in Medical Science*, 24(2), 269–283.
- Retzepi, M., Tonetti, M., & Donos, N. (2007a). Gingival blood flow changes following periodontal access flap surgery using laser Doppler flowmetry. *Journal of Clinical Periodontology*, 34(5), 437–443.
- Retzepi, M., Tonetti, M., & Donos, N. (2007b). Comparison of gingival blood flow during healing of simplified papilla preservation and modified Widman flap surgery: A clinical trial using laser Doppler flowmetry. *Journal of Clinical Periodontology*, 34(10), 903–911.
- Reuther, W. J., Hale, B., Matharu, J., Blythe, J. N., & Brennan, P. A. (2016). Do you mind if I vape? Immediate effects of electronic cigarettes on perfusion in buccal mucosal tissue—a pilot study. *British Journal of Oral and Maxillofacial Surgery*, 54(3), 338–341.
- Riva, C. E., Geiser, M., & Petrig, B. L. (2010). Ocular blood flow assessment using continuous laser Doppler flowmetry. *Acta Ophthalmologica*, 88(6), 622–629.
- Roeykens, H. J., Deschepper, E., & De Moor, R. J. (2016). Laser Doppler flowmetry: Reproducibility, reliability, and diurnal blood flow variations. *Lasers in Medical Science*, 31(6), 1083–1092.
- Sakr, Y., Gath, V., Oishi, J., Klinzing, S., Simon, T., Reinhart, K., et al. (2010). Characterization of buccal microvascular response in patients with septic shock. *European Journal of Anaesthesiology*, 27(4), 388–394.
- Setzer, F. C., Challagulla, P., Kataoka, S. H., & Trope, M. (2013). Effect of tooth isolation on laser Doppler readings. *International Endodontic Journal*, 46(6), 517–522.
- Shuler, R. L. (1968). Effect of cigarette smoking on the circulation of the oral mucosa. *Journal of Dental Research*, 47(6), 910–915.
- Singh, D. B., Stansby, G., & Harrison, D. K. (2008). Assessment of oxygenation and perfusion in the tongue and oral mucosa by visible spectrophotometry and laser Doppler flowmetry in healthy subjects. *Advances in Experimental Medicine and Biology*, 614, 227–233.
- Stern, M. D. (1975). In vivo evaluation of microcirculation by coherent light scattering. *Nature*, 254(5495), 56–58.
- Svalestad, J., Hellem, S., Vaagbø, G., Irgens, A., & Thorsen, E. (2010). Reproducibility of transcutaneous oximetry and laser Doppler flowmetry in facial skin and gingival tissue. *Microvascular Research*, 79(1), 29–33.
- Svalestad, J., Thorsen, E., Vaagbø, G., & Hellem, S. (2014). Effect of hyperbaric oxygen treatment on oxygen tension and vascular capacity in irradiated skin and mucosa. *International Journal of Oral and Maxillofacial Surgery*, 43(1), 107–112.
- Verdonck, H. W., Meijer, G. J., Kessler, P., Nieman, F. H., De Baat, C., & Stoelinga, P. J. (2009). Assessment of bone vascularity in the anterior mandible using laser Doppler flowmetry. *Clinical Oral Implants Research*, 20(2), 140–144.
- Vongsavan, N., & Matthews, B. (1993). Some aspects of the use of laser Doppler flow meters for recording tissue blood flow. *Experimental Physiology*, 78(1), 1–14.